

Rad^{to}RadLearning

Focused tips from our experts

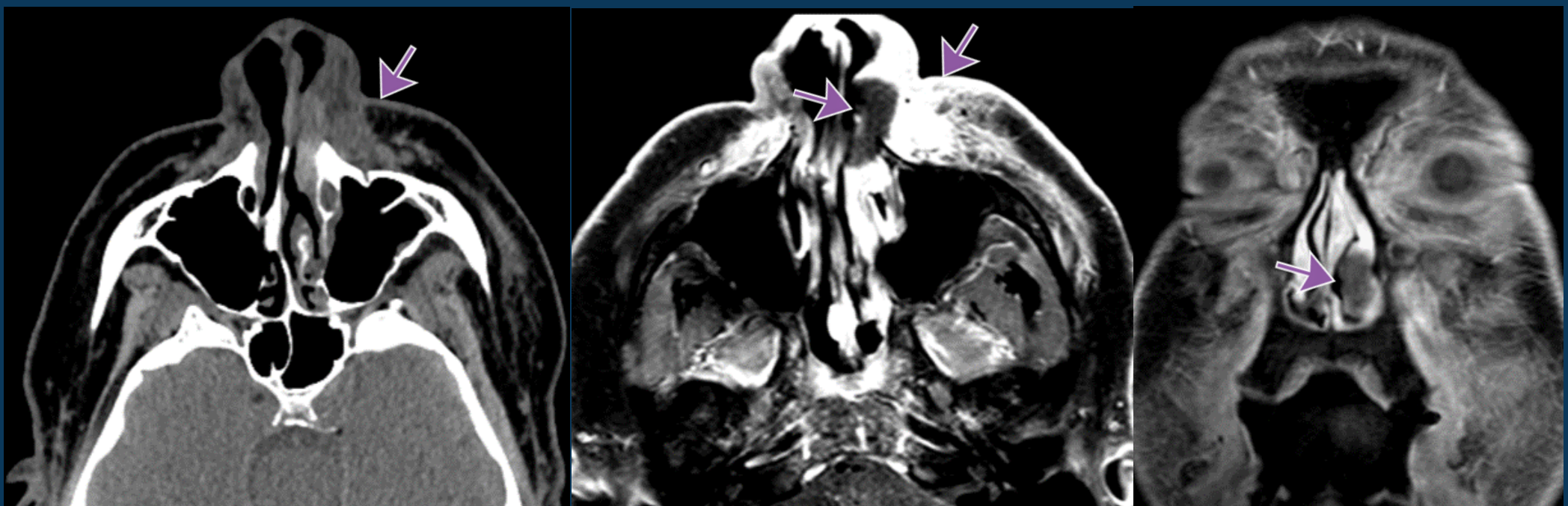
Invasive Fungal Sinusitis

NEURORADIOLOGY NATIONAL SUBSPECIALTY DIVISION



PEER LEARNING OPPORTUNITY

Rapidly progressing condition with 30-80% mortality.



Sinus opacification with bone erosion, soft tissue infiltrate and non-enhancing mucosa.



PRACTICAL INSIGHTS

- Immunocompromised and diabetic patients.
- Commonly start from middle turbinates.
- Can spread via perivascular channels without bone erosions.
- Mimics malignancy.



LOOK FOR PERIANTRAL STRANDING IN IMMUNOCOMPROMISED PATIENT.

CLINICAL VALUE