

Rad^{to}RadLearning

Focused tips from our experts

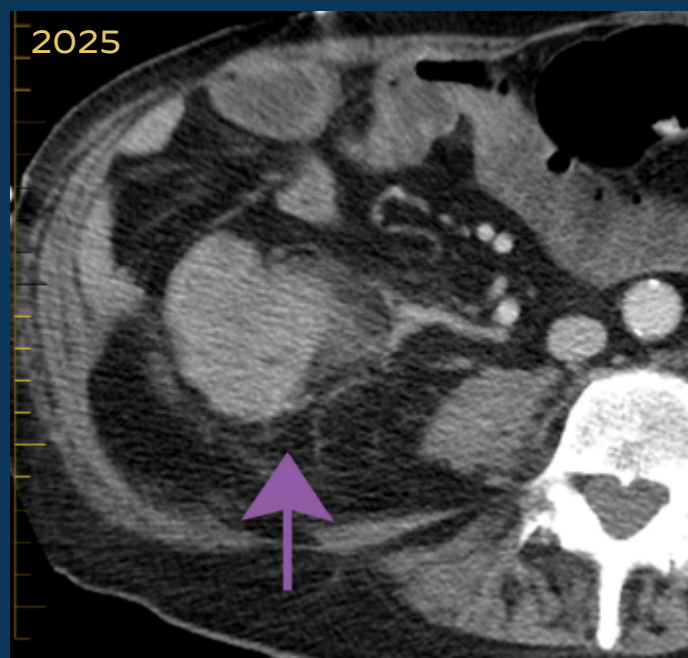
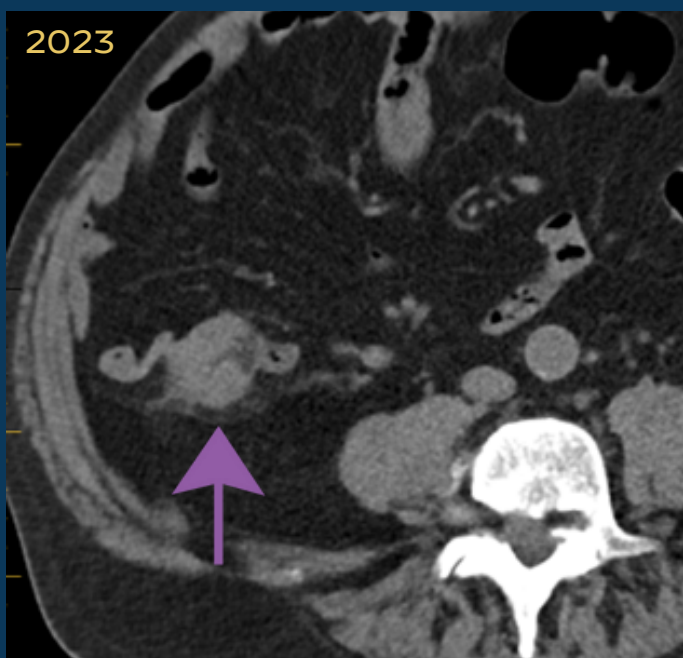
Incidental Colon Cancer

RP NATIONAL PATIENT SAFETY COMMITTEE



PEER LEARNING OPPORTUNITY

Colon cancer can go undetected in up to 20% of abdomen CT subsequently proven to have colon cancer at colonoscopy.



Analyze colonic wall thickening and adjacent stranding, vessel engorgement and lymphadenopathy on routine abdomen CT.



PRACTICAL INSIGHTS

- Reasons for missed diagnosis: small tumor size (less than 3 cm), lack of fat stranding, lack of lymphadenopathy, lack of vessel engorgement.
- Consider use of follow-up CT colonography or colonoscopy for suspicious lesions.



CAREFULLY INSPECT THE COLON ON EVERY ABDOMEN CT



CLINICAL VALUE