

Rad^{to}RadLearning

Focused tips from our experts

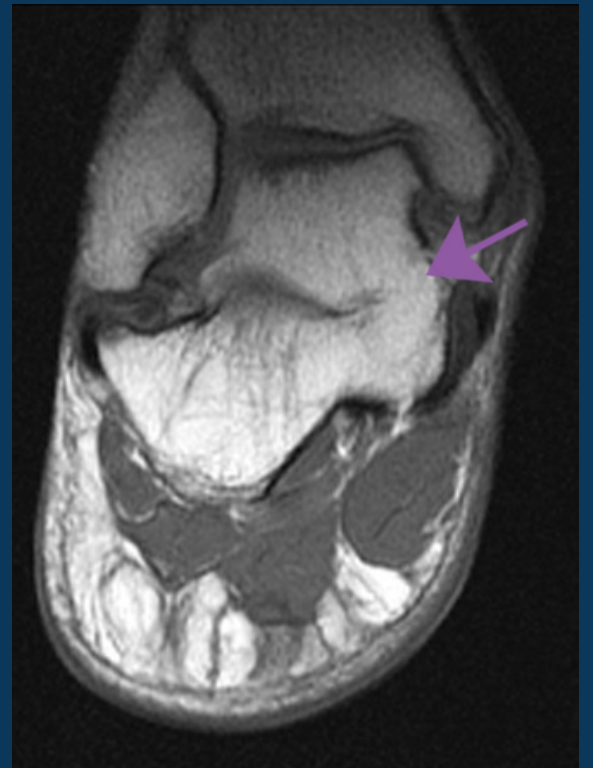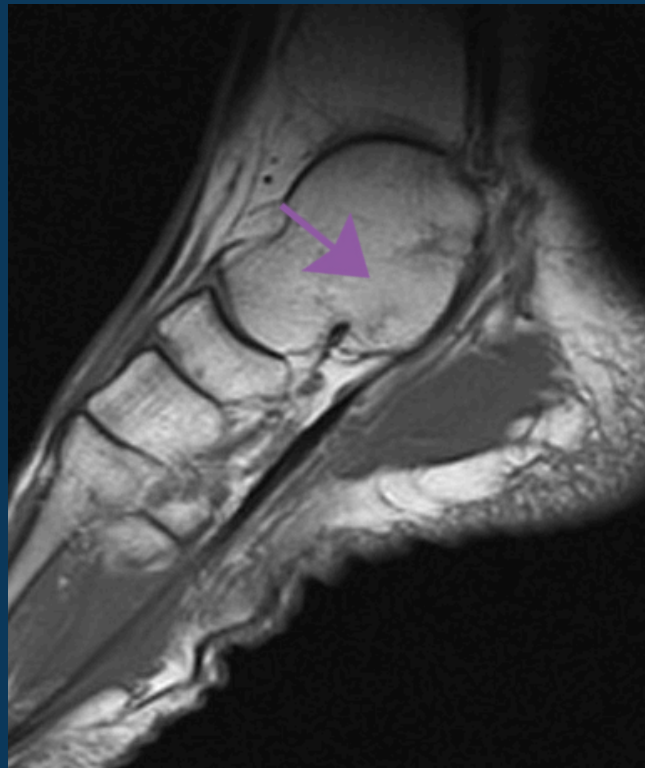
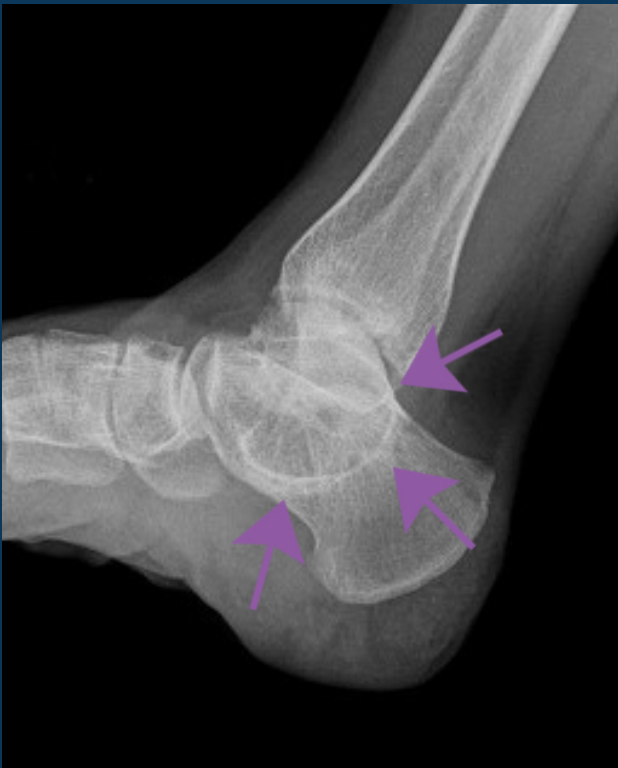Talocalcaneal Coalition

MSK NATIONAL SUBSPECIALTY DIVISION



PEER LEARNING OPPORTUNITY

The most common tarsal coalitions are easily missed if not part of your search pattern.



Arrows denote the radiographic “C-sign,” representing osseous fusion of the middle subtalar joint on MRI.



PRACTICAL INSIGHTS

- Age of onset: 12-15 years old.
- Represents 45% of all tarsal coalitions.
- Coalitions may be fibrous, cartilaginous or osseous.
- Radiographic “C-sign” on lateral view represents a fused talus and sustentaculum tali across either the medial aspect of the posterior subtalar joint or the middle subtalar joint.



EARLY DIAGNOSIS CAN PREVENT ACCELERATED OSTEOARTHRITIS.

CLINICAL VALUE