

Rad^{to}Rad Learning

Focused tips from our experts

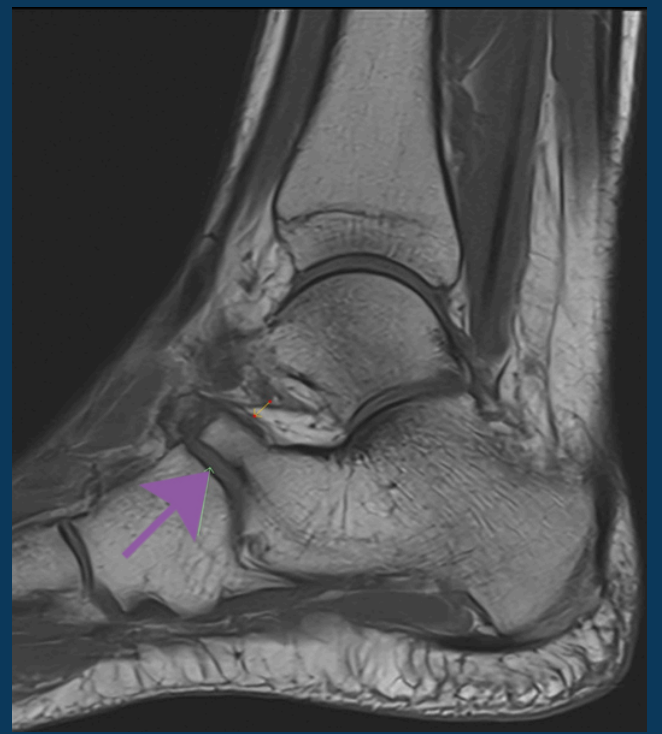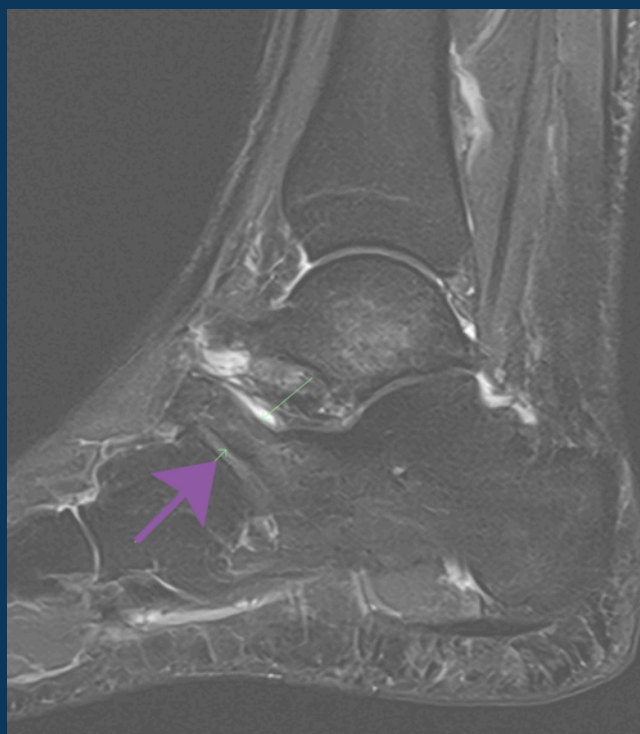
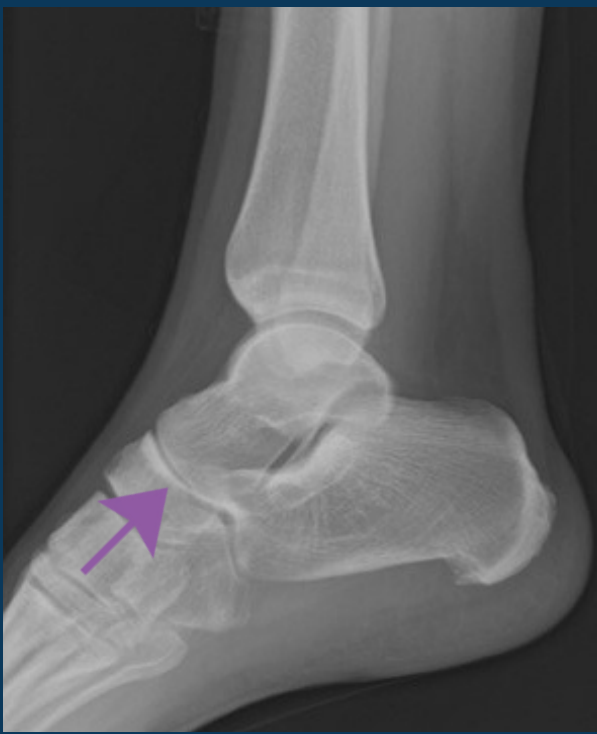Calcaneonavicular Coalition

MSK NATIONAL SUBSPECIALTY DIVISION



PEER LEARNING OPPORTUNITY

The most common tarsal coalitions are easily missed if not part of your search pattern.



Arrow denotes an elongated anterior process of the calcaneus or "anteater nose sign."



PRACTICAL INSIGHTS

- Age of onset: 8-12 years old.
- Represents 53% of all tarsal coalitions.
- Coalitions may be fibrous, cartilaginous or osseous.
- Radiographic "anteater nose sign" represents an elongated anterior process of the calcaneus approaching the navicular.



EARLY DIAGNOSIS CAN PREVENT ACCELERATED OSTEOARTHRITIS.

CLINICAL VALUE