

Rad^{to}RadLearning

Focused tips from our experts

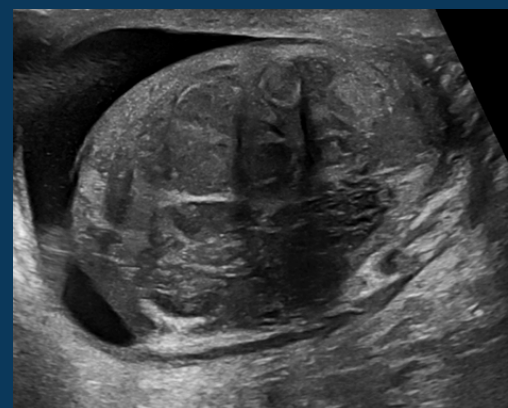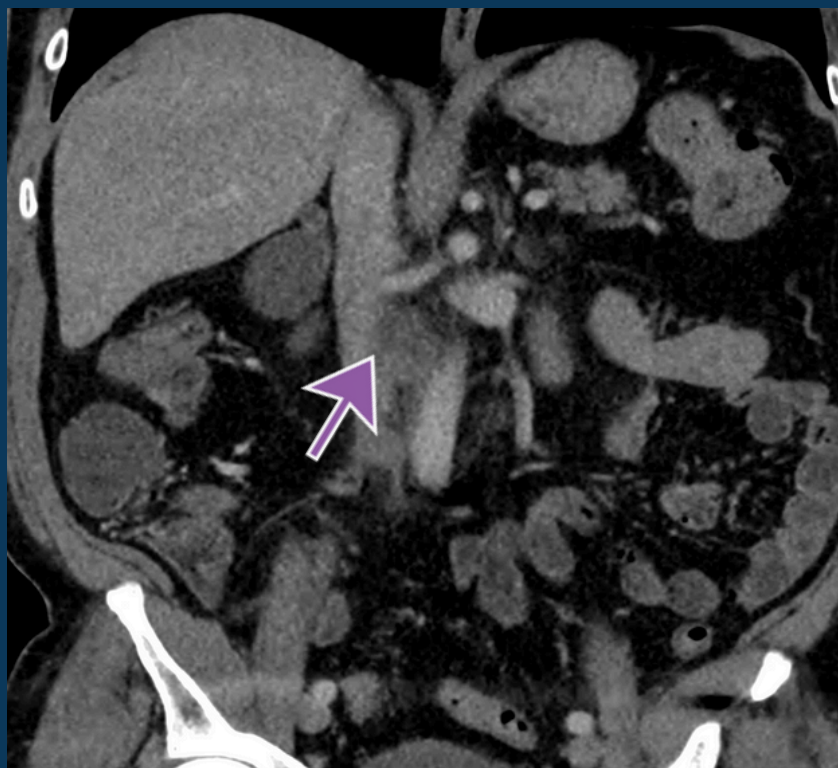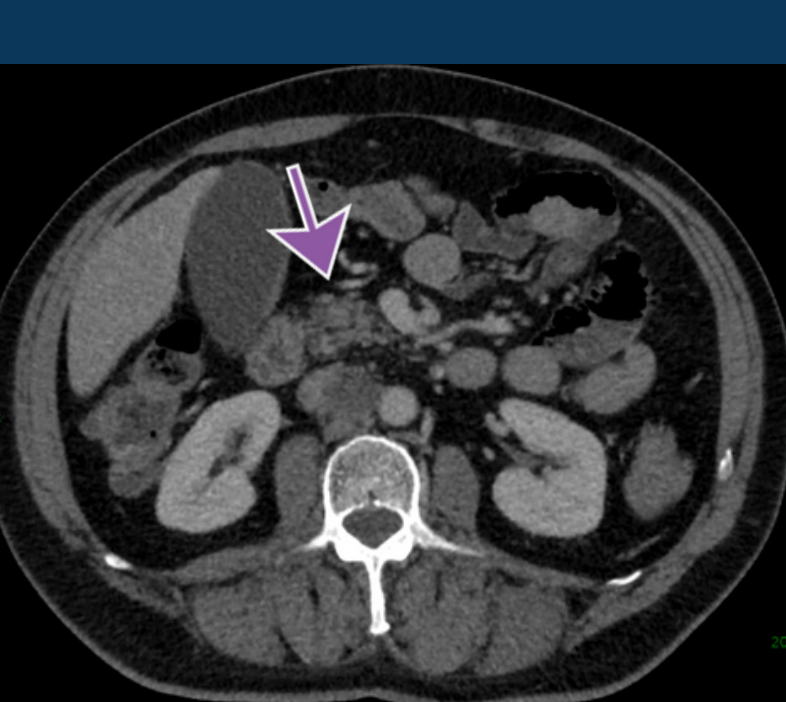
Abdominal Lymphadenopathy

BODY IMAGING NATIONAL SUBSPECIALTY DIVISION



PEER LEARNING OPPORTUNITY

62-year-old male presented to ED with one-month history of RLQ pain, worsening in last 48 hours. Suspecting appendicitis, obtained CT abdomen/pelvis.



Retroperitoneal lymphadenopathy may be concerning for occult testicular malignancy in adult males.



PRACTICAL INSIGHTS

- Enlarged right testicle with multiple heterogenous masses, scattered calcifications consistent with testicular neoplasm.
- Alpha fetal protein: 68 nanograms/mL (normal 0-9).
- Final pathology: Mixed germ cell tumor, 80% embryonal and 20% seminoma with spermatic cord invasion.



OCCULT ADENOPATHY IN MALES SHOULD PROMPT SCROTAL US.

CLINICAL VALUE