

Rad^{to}RadLearning

Focused tips from our experts

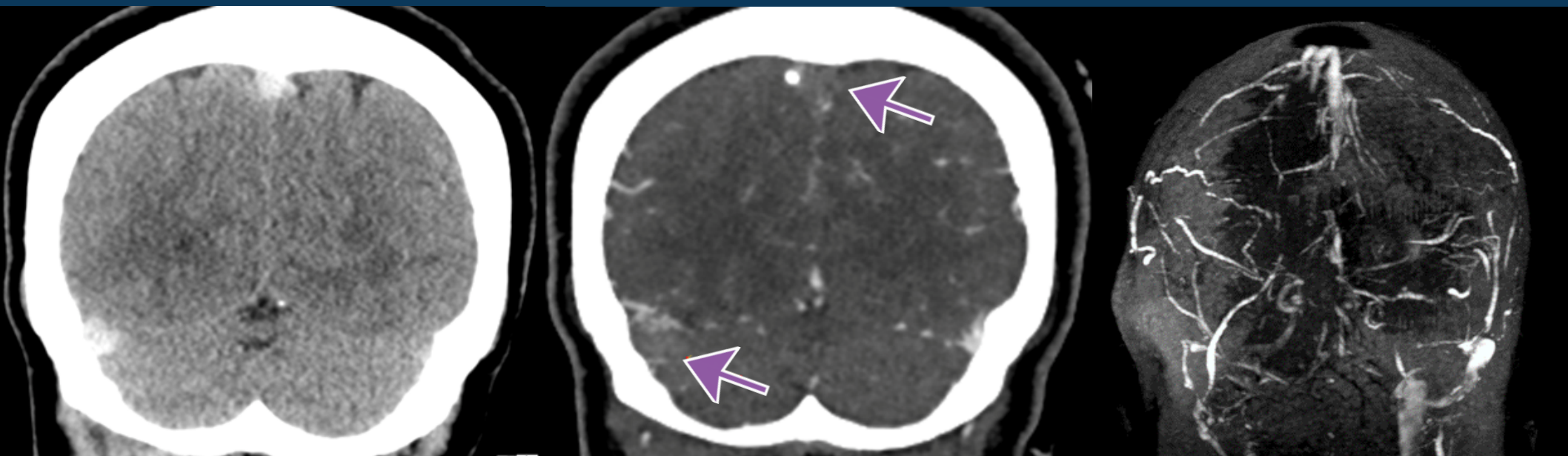
Venous Sinus Thrombosis

NEURORADIOLOGY NATIONAL SUBSPECIALTY DIVISION



PEER LEARNING OPPORTUNITY

If missed, there are serious consequences, such as stroke and hemorrhage.



Hyperdense asymmetric sinus on CT and filling defect on CTV/MRV



PRACTICAL INSIGHTS

- Malignancy, pregnancy, use of oral contraceptives, thrombophilia, and local infections are predisposing factors.
- On MRI, look for restricted diffusion/T1 shortening/susceptibility in the sinuses and nonterritorial edema and infarcts.



IF CLINICAL SUSPICIAN IS HIGH, BUT CT NEGATIVE, RECOMMEND CTV/MRV.

CLINICAL VALUE