

Rad^{to}RadLearning

Focused tips from our experts

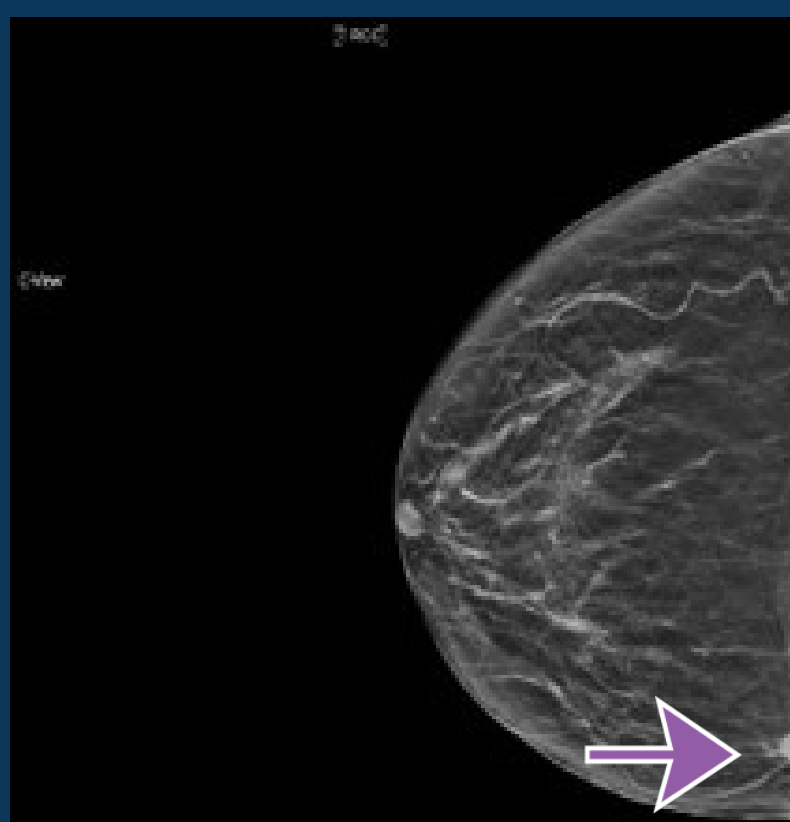
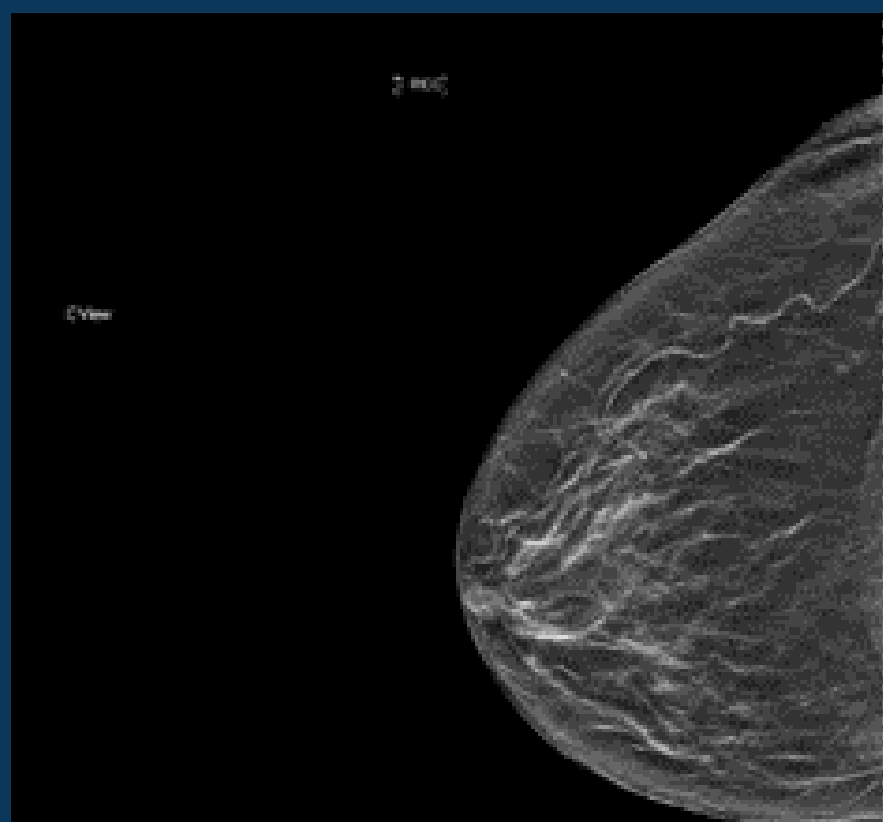
Technique Matters

BREAST IMAGING NATIONAL SUBSPECIALTY DIVISION



PEER LEARNING OPPORTUNITY

Do not accept suboptimal patient positioning.



Right CC view is laterally exaggerated laterally, excluding medial tissue.



PRACTICAL INSIGHTS

- On a CC view, the posterior nipple line should bisect the breast into equal halves, with only fat or muscle in the retrogladular space.
- On an MLO view, the pectoralis muscle should extend to the posterior nipple line with a convex anterior margin of the pectoralis muscle. The inframammary fold should be open.



YOU CAN'T FIND CANCERS YOU CAN'T SEE

CLINICAL VALUE