

# Rad<sup>to</sup>RadLearning

*Focused tips from our experts*

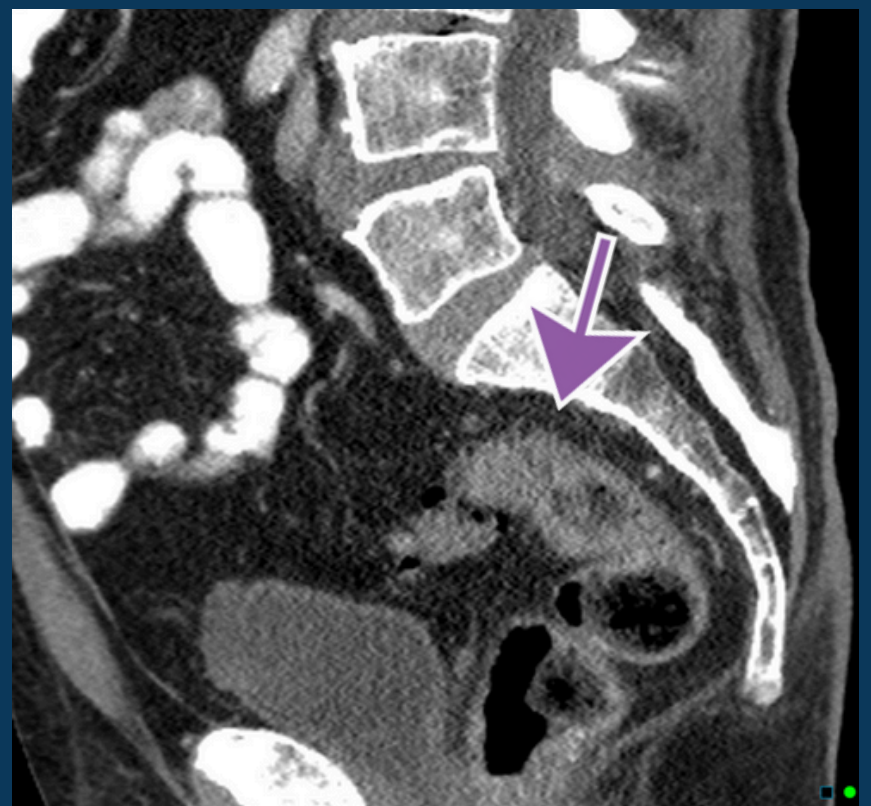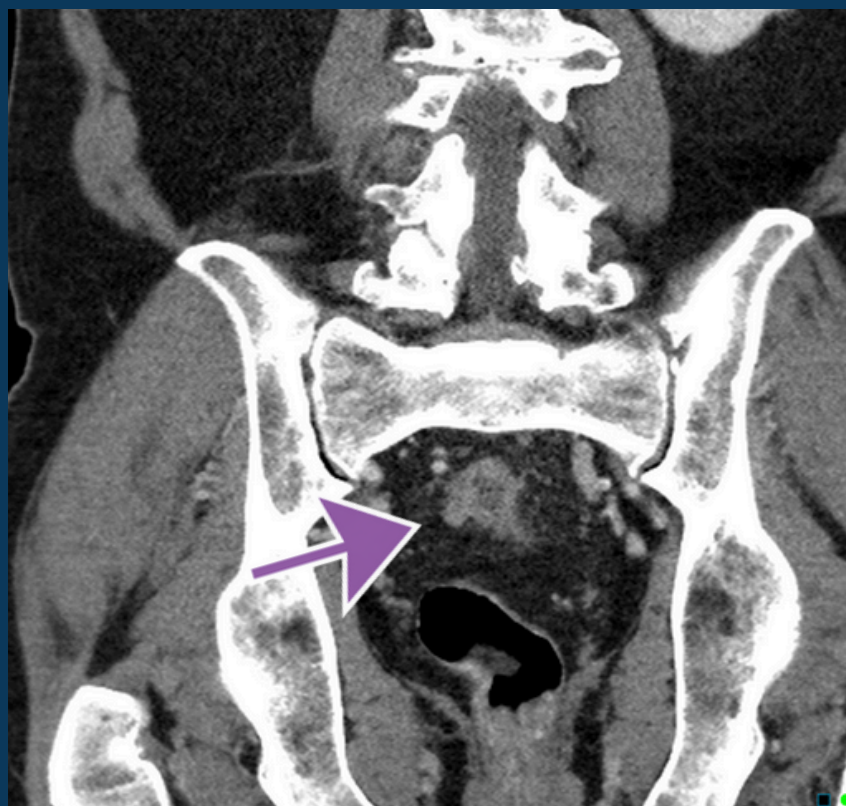
## Colon Cancer Awareness

BODY IMAGING NATIONAL SUBSPECIALTY DIVISION



### PEER LEARNING OPPORTUNITY

Since the 1990s the incidence of colon cancer has doubled in individuals under the age of 45.



*Arrows show tumor with mild fat infiltration. PET CT confirms focal lesion + adjacent pathologic lymph nodes.*



### PRACTICAL INSIGHTS

- Final Pathology: Invasive moderately differentiated adenocarcinoma
- Not all wall thickening is inflammation
- Focal wall thickening should raise suspicion for cancer



**RECOMMEND FOLLOW UP COLONOSCOPY FOR ANY BOWEL PATHOLOGY**

## CLINICAL VALUE