

# Rad<sup>to</sup>Rad Learning

Focused tips from our experts

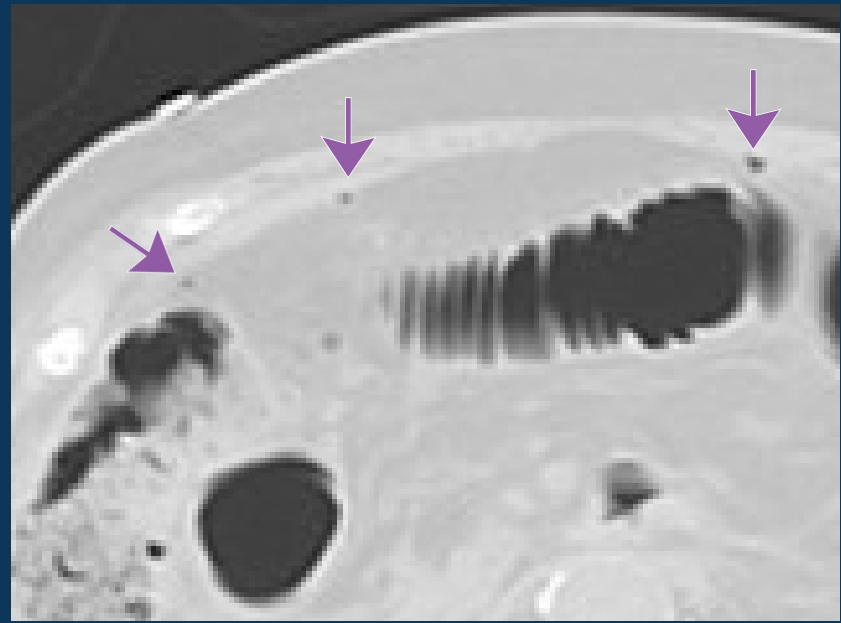
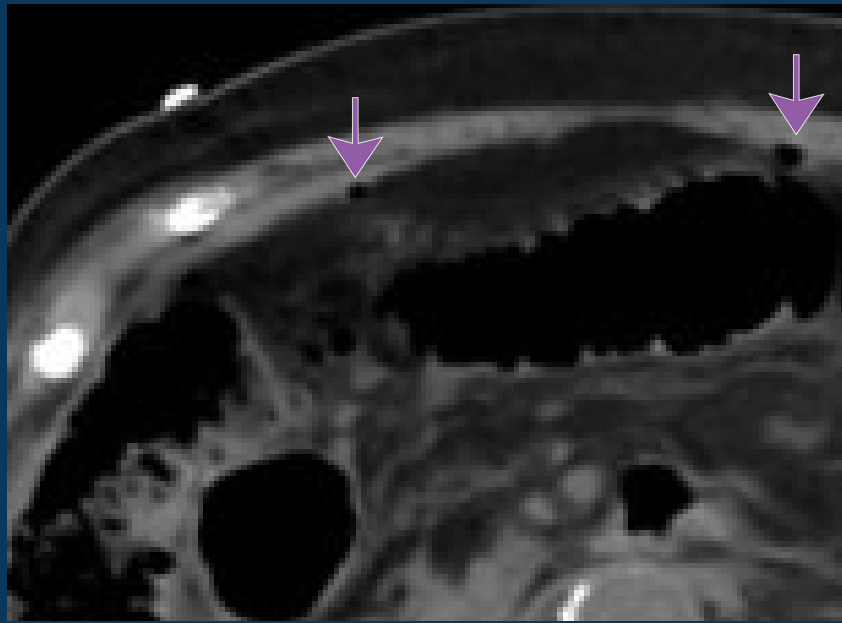
## Abdominal Free Air

NATIONAL PATIENT SAFETY COMMITTEE



### PEER LEARNING OPPORTUNITY

Retrospective studies demonstrate high morbidity and mortality due to peritonitis and sepsis, occurring up to 33% of patients.



*View image using lung window setting to increase sensitivity and detect subtle foci of extraluminal gas*



### PRACTICAL INSIGHTS

- Free fluid, bowel wall thickening, and inflammation are commonly associated findings.
- Consider reviewing sagittal and coronal reformatted images.



**USE LUNG WINDOW IN COMPLEX ABD EXAMS**

## CLINICAL VALUE