# Rad to Rad Learning: Incidental Intra-Cardiac Lesions

**The Radiology Partners (RP) Cardiothoracic Imaging National Subspecialty Division (NSD) presents our newest Rad to Rad Learning case.**

---

## Peer Learning Opportunity

**Although infrequent, intra-cardiac thrombi or masses have significant ramifications and can result in pulmonary or systemic embolization.**

## Incidental Intra-Cardiac Lesions

**All three images are from CT abdomen/pelvis exams.**

**1. Left atrial appendage thrombus**

**2. Right artial mass.**

**3. Left ventricular mass.**

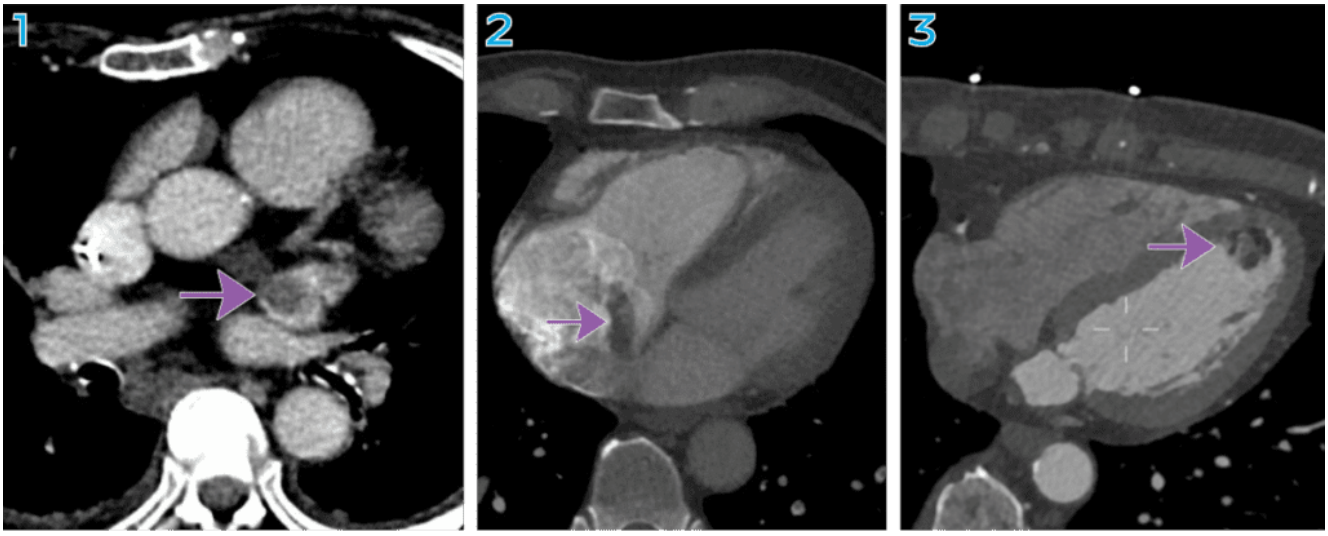


*Shared to improve patient safety and healthcare delivery in the provision of radiology services. The circumstances and facts are changed, altered, or deidentified to preserve confidentiality. Privileges have not been waived.*

---

## Practical Insights

- **Though motion artifacts and contrast flow artifacts can make the heart chambers difficult to assess, include them in your search patterns of non-cardiac examinations.**

---

## Think beyond heart size and coronary calcifications when reviewing the heart.

The Cardiothoracic Imaging National Subspecialty Division (NSD) is part of RP's Clinical Value Team, which works to

elevate patient care and enhance value through innovation, collaboration and education. To advance this goal, our radiologists and advanced practice providers are committed to sharing peer learning as valuable reminders and insights about what we encounter in our day-to-day practice. Check back here and on X, LinkedIn and Instagram to see these common cases and our findings.

Visit the Clinical Resources page for more cases and to see what we've developed to enhance best practice recommendations, elevate image quality and patient care and update current standards throughout RP's network of practices, all to deliver excellent radiology services to patients, referring clinicians and client partners.




*Radiology Partners, through its owned and affiliated practices, is a leading physician-led and physician-owned technology-enabled radiology practice in the U.S. For the latest news from RP, follow us on X, LinkedIn, Instagram, YouTube and the blog.*

---

# Rad to Rad Learning:

# Ileocolic vs. Small Bowel Intussesception

**The Radiology Partners (RP) Pediatric Radiology National Subspecialty Division (NSD) presents our newest Rad to Rad Learning case.**

---

## Peer Learning Opportunity

**Small bowel intussusceptions do not typically require management but can be mistaken for the urgent diagnosis of ileocolic intussusception.**

## Ileocolic vs. Small Bowel Intussusception

- **Images 1 & 2: (purple arrow)Mesenteric fat and (yellow arrow) lymph node inside ileocolic intussusception.**
- **Image 3: Small bowel intussusception.**

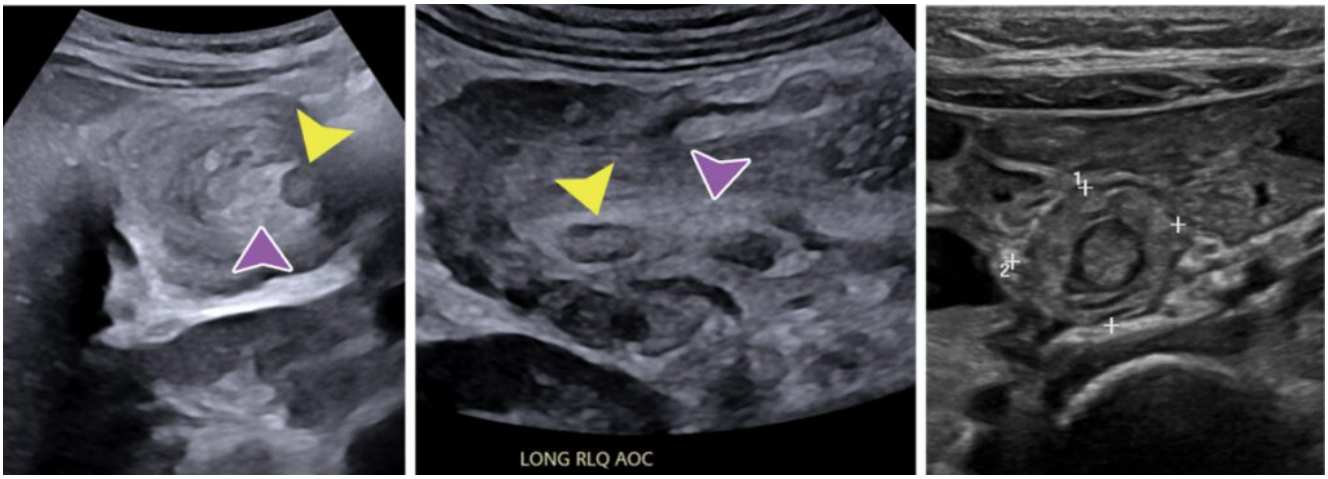


*Shared to improve patient safety and healthcare delivery in the provision of radiology services. The circumstances and facts are changed, altered, or deidentified to preserve confidentiality. Privileges have not been waived.*

---

## Practical Insights

- **Ileocolic Intussusception:**
  - Location: RUQ or RLQ
  - Characteristics: size >2cm, mesenteric fat, lymph node
- **Small bowel intusssusception:**
  - LocationL LLQ or LUQ
  - Characteristics: size <2cm, no fat, no lymph node
- **If uncertain, another scan can be obtained in ~30 minutes.**

---

## <2cm LLQ intussusceptions are likely physiologic. If uncertain, reassess.

The Pediatric Radiology National Subspecialty Division (NSD) is part of RP's Clinical Value Team, which works to elevate patient care and enhance value through innovation, collaboration and education. To advance this goal, our radiologists and advanced practice providers are committed to sharing peer learning as valuable reminders and insights about what we encounter in our day-to-day practice. Check back here and on X, LinkedIn and Instagram to see these common cases and our findings.

Visit the Clinical Resources page for more cases and to see what we've developed to enhance best practice recommendations, elevate image quality and patient care and update current standards throughout RP's network of practices, all to deliver excellent radiology services to patients, referring clinicians and client partners.




*Radiology Partners, through its owned and affiliated practices, is a leading physician-led and physician-owned technology-enabled radiology practice in the U.S. For the latest news from RP, follow us on X, LinkedIn, Instagram, YouTube and the blog.*

# Rad to Rad Learning: Carotid Cavernous Fistula

**The Radiology Partners (RP) Neuroradiology National Subspecialty Division (NSD) presents our newest Rad to Rad Learning case.**

---

## Peer Learning Opportunity

**Permanent vision loss is seen in 10-20% of untreated cases. Intracranial hemorrhages or venous infarctions are seen in 5-10% of cases.**

## Carotid Cavernous Fistula

- **Asymmetric enhancement of left cavernous sinus and dilated left superior and inferior ophthalmic veins in arterial phase.**
- **Type D Fistula is supplied from branches of external carotid arteries**

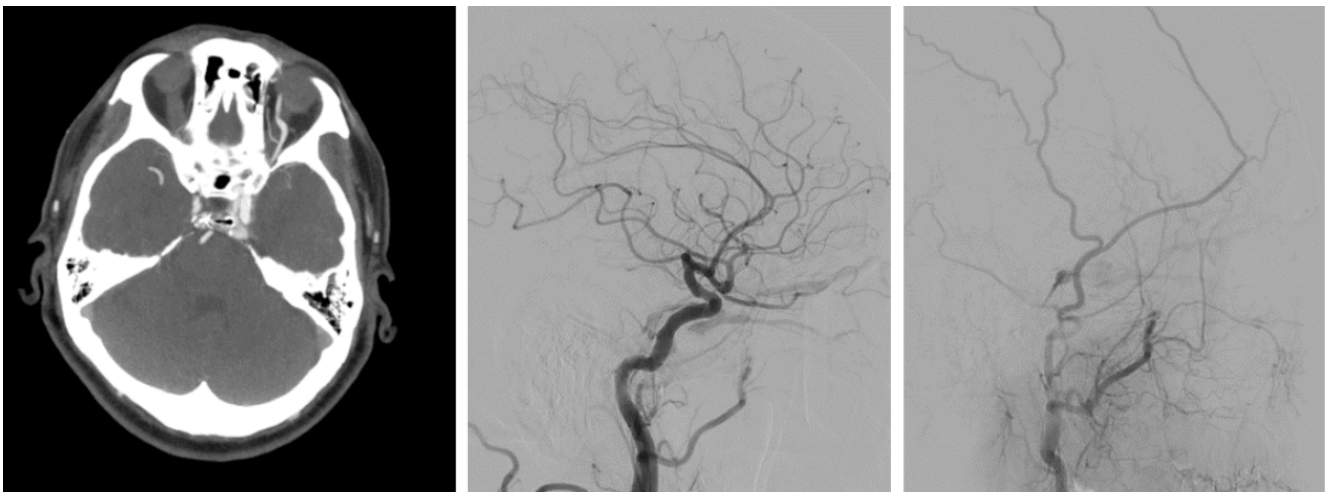

*Shared to improve patient safety and healthcare delivery in the provision of radiology services. The circumstances and facts are changed, altered, or deidentified to preserve confidentiality. Privileges have not been waived.*

---

## Practical Insights

- **Classic clinical triad of pulsatile proptosis, orbital bruit and conjunctival chemosis is often incomplete.**
- **Cortical venous reflux indicates high risk of hemorrhage.**
- **High-flow (Type A) CCF are often traumatic, develop abruptly and have worse prognosis.**
- **Up to 70% of low-flow (Types B, C, D) may resolve spontaneously.**

**Cranial Nerva palsies II, IV, and VI are often reported.**

---

## Dynamic MRA or CTA initially, DSA for confirmation and treatment planning.

The Neuroradiology National Subspecialty Division (NSD) is part of RP's Clinical Value Team, which works to elevate patient care and enhance value through innovation, collaboration and education. To advance this goal, our radiologists and advanced practice providers are committed to sharing peer learning as valuable reminders and insights about what we encounter in our day-to-day practice. Check back here and on X, LinkedIn and Instagram to see these common cases and our findings.

Visit the Clinical Resources page for more cases and to see what we've developed to enhance best practice recommendations, elevate image quality and patient care and update current standards throughout RP's network of practices, all to deliver excellent radiology services to patients, referring clinicians and client partners.




*Radiology Partners, through its owned and affiliated practices, is a leading physician-led and physician-owned technology-enabled radiology practice in the U.S. For the latest news from RP, follow us on*

*X*, *LinkedIn*, *Instagram*, *YouTube* and *the blog*.

---

# Rad to Rad Learning: Post-Bariatric Surgery Complications

## The Radiology Partners (RP) National Quality and Safety Committee presents our newest Rad to Rad Learning case.

---



## Peer Learning Opportunity

**Bariatric surgeries have a high incidence of varied complications, such as staple line dehiscence, perforation, obstruction, vascular occlusion and postoperative volvulus.**

## Post-Bariatric Surgery Complications

**Distinctive mesenteric vessel “swirl” visible with postoperative volvulus.**

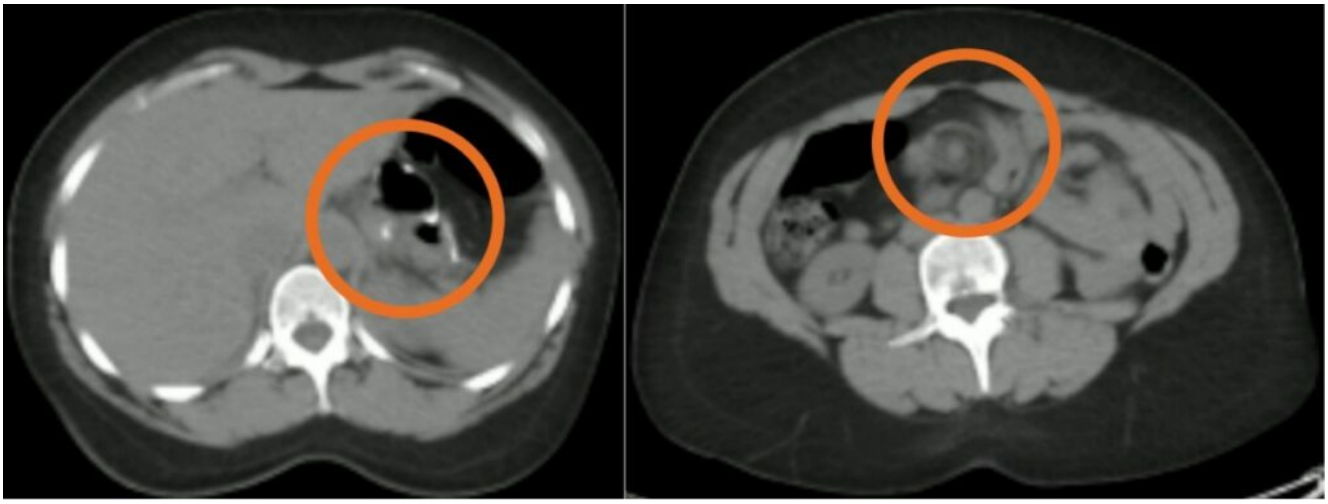

*Shared to improve patient safety and healthcare delivery in the provision of radiology services. The circumstances and facts are changed, altered, or deidentified to preserve confidentiality. Privileges have not been waived.*

---

## Practical Insights

- **Particular attention should be paid to the integrity of the staple line, condition of the bowel and patency of mesenteric vessels.**
- **Knowledge of typical post-operative anatomy is essential for accurate interpretation.**
- **These studies should be performed with oral and intravenous contrast unless**

**contraindicated.**

---

## 🔔 Recommend oral and intravenous contrast on bariatric surgery patients.

The National Quality and Safety Committee is part of RP's Clinical Value Team, which works to elevate patient care and enhance value through innovation, collaboration and education. To advance this goal, our radiologists and advanced practice providers are committed to sharing peer learning as valuable reminders and insights about what we encounter in our day-to-day practice. Check back here and on X, LinkedIn and Instagram to see these common cases and our findings.

Visit the Clinical Resources page for more cases and to see what we've developed to enhance best practice recommendations, elevate image quality and patient care and update current standards throughout RP's network of practices, all to deliver excellent radiology services to patients, referring clinicians and client partners.




*Radiology Partners, through its owned and affiliated practices, is a leading physician-led and physician-owned technology-enabled radiology practice in the U.S. For the latest news from RP, follow us on*

*X, LinkedIn, Instagram, YouTube and the blog.*

---

# Rad to Rad Learning: Pyloric Stenosis

## The Radiology Partners (RP) Pediatric Radiology National Subspecialty Division (NSD) presents our newest Rad to Rad Learning case.

The Pediatric Radiology NSD is part of RP's Clinical Value Team, which works to elevate patient care and enhance value through innovation, collaboration and education. To advance this goal, our radiologists and advanced practice providers are committed to sharing peer learning as valuable reminders and insights about what we encounter in our day-to-day practice.

Check back here and on X, LinkedIn and Instagram to see these common cases and our findings.




Visit the [Clinical Resources page] for more cases and to see what we've developed to enhance best practice recommendations, elevate image quality and patient care and update current standards throughout RP's network of practices, all to deliver excellent radiology services to patients, referring clinicians and client partners.

*Radiology Partners, through its owned and affiliated practices, is a leading physician-led and physician-owned technology-enabled radiology practice in the U.S. For the latest news from RP, follow us on X, LinkedIn, Instagram, YouTube and the blog.Shared to improve patient safety and healthcare delivery in the provision of radiology services. The circumstances and facts are changed, altered, or deidentified to preserve confidentiality. Privileges have not been waived.*

---

# Rad to Rad Learning: Renal Angiomyolipoma

## The Radiology Partners (RP) Interventional Radiology (IR) National Subspecialty Division (NSD) presents our newest Rad to Rad Learning case.

The IR NSD is part of RP's Clinical Value Team, which works to elevate patient care and enhance value through innovation, collaboration and education. To advance this goal, our radiologists and advanced practice providers are committed to sharing peer learning as valuable reminders and insights about what we encounter in our day-to-day practice.

Check back here and on X, LinkedIn and Instagram to see these common cases and our findings.




Visit the [Clinical Resources page] for more cases and to see what we've developed to enhance best practice recommendations, elevate image quality and patient care and update current standards throughout RP's network of practices, all to deliver excellent radiology services to patients, referring clinicians and client partners.

*Radiology Partners, through its owned and affiliated practices, is a leading physician-led and physician-owned technology-enabled radiology practice in the U.S. For the latest news from RP, follow us on X, LinkedIn, Instagram, YouTube and the blog.Shared to improve patient safety and healthcare delivery in the provision of radiology services. The circumstances and facts are changed, altered, or deidentified to preserve confidentiality. Privileges have not been waived.*

---

# Rad to Rad Learning: CT Left Atrial Appendage Occluder Device Thrombosis & Leak

## The Radiology Partners (RP) Cardiothoracic Imaging National Subspecialty Division (NSD) presents two of our newest Rad to Rad Learning cases.

The Cardiothoracic Imaging NSD is part of RP's Clinical Value Team, which works to elevate patient care and enhance value through innovation, collaboration and education. To advance this goal, our radiologists and advanced practice providers are committed to sharing peer learning as valuable reminders and insights about what we encounter in our day-to-day practice.

Check back here and on X, LinkedIn and Instagram to see these common cases and our findings.

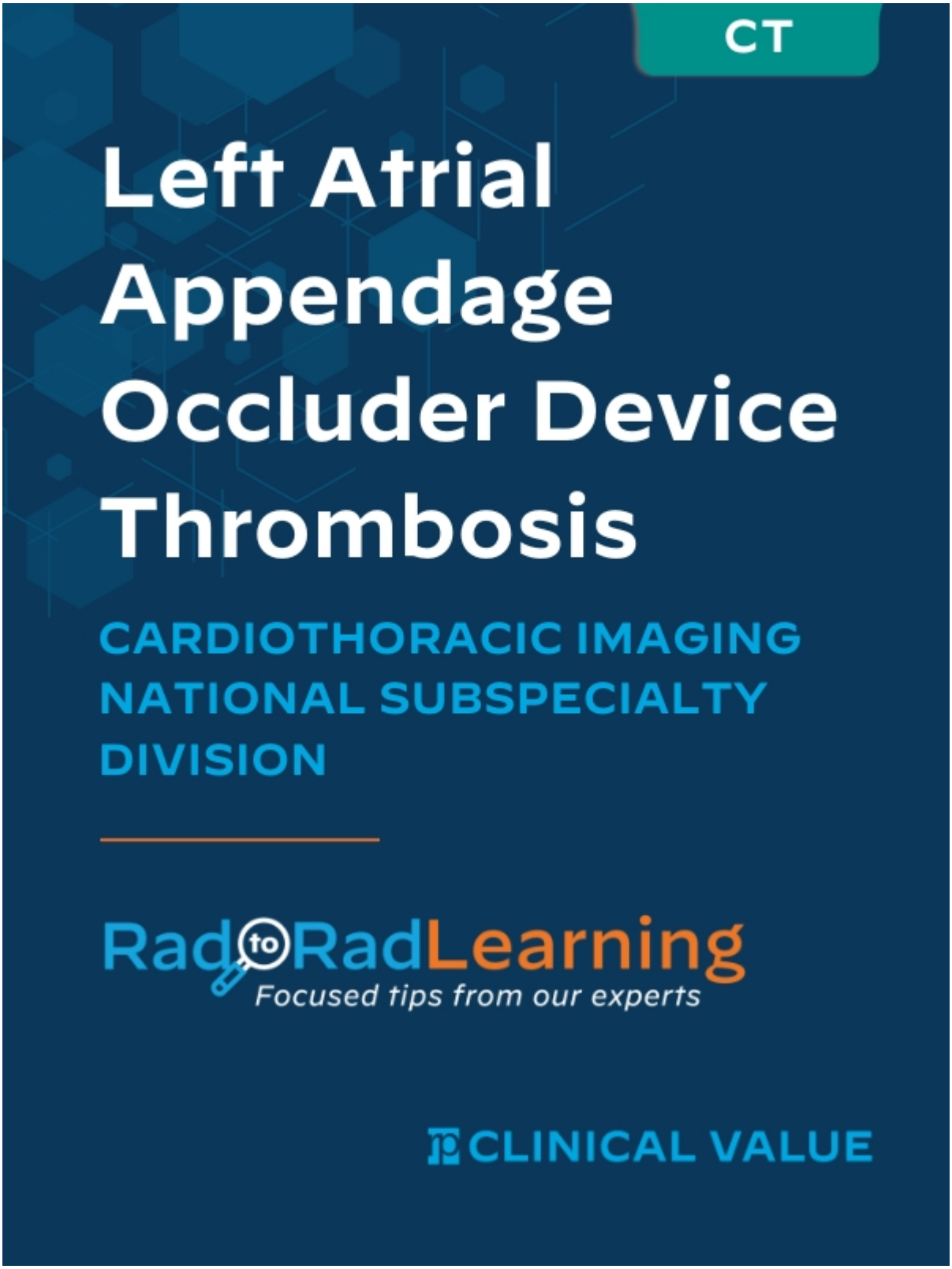

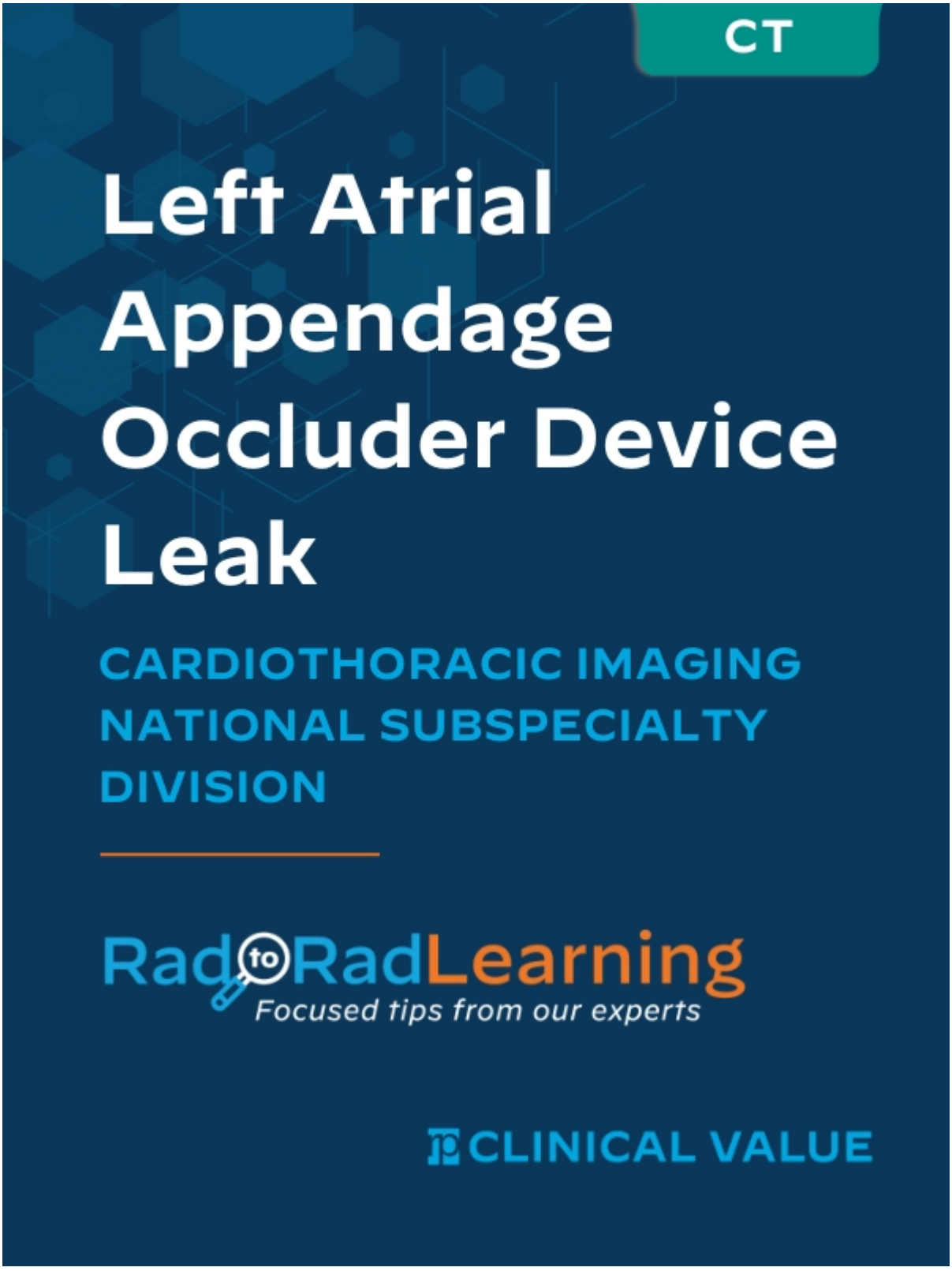


Visit the [Clinical Resources page] for more cases and to see what we've developed to enhance best practice recommendations, elevate image quality and patient care and update current standards throughout RP's network of practices, all to deliver excellent radiology services to patients, referring clinicians and client partners.

*Radiology Partners, through its owned and affiliated practices, is a leading physician-led and physician-owned technology-enabled radiology practice in the U.S. For the latest news from RP, follow us on X, LinkedIn, Instagram, YouTube and the blog.Shared to improve patient safety and healthcare delivery in the provision of radiology services. The circumstances and facts are changed, altered, or deidentified to preserve confidentiality. Privileges have not been waived.*

---

# Rad to Rad Learning: Implant Obscured Mass

## The Radiology Partners (RP) Breast Imaging National Subspecialty Division (NSD) presents our newest Rad to Rad Learning case.

The Breast Imaging NSD is part of RP's Clinical Value Team, which works to elevate patient care and enhance value through innovation, collaboration and education. To advance this goal, our radiologists and advanced practice providers are committed to sharing peer learning as valuable reminders and insights about what we encounter in our day-to-day practice.

Check back here and on X, LinkedIn and Instagram to see these common cases and our findings.




Visit the Clinical Resources page for more cases and to see what we've developed to enhance best practice recommendations, elevate image quality and patient care and update current standards throughout RP's network of practices, all to deliver excellent radiology services to patients, referring clinicians and client partners.

*Radiology Partners, through its owned and affiliated practices, is a leading physician-led and physician-owned radiology practice in the U.S. For the latest news from RP, follow us on X, LinkedIn, Instagram, YouTube and the blog.Shared to improve patient safety and healthcare delivery in the provision of radiology services. The circumstances and facts are changed, altered, or deidentified to preserve confidentiality. Privileges have not been waived.*

---

# Rad to Rad Learning: Ovarian/Adnexal Torsion

## The Radiology Partners (RP) Body Imaging National Subspecialty Division (NSD) presents our newest Rad to Rad Learning case.

The Body Imaging NSD is part of RP's Clinical Value Team, which works to elevate patient care and enhance value through innovation, collaboration and education. To advance this goal, our radiologists and advanced practice providers are committed to sharing peer learning as valuable reminders and insights about what we encounter in our day-to-day practice.

Check back here and on X, LinkedIn and Instagram to see these common cases and our findings.

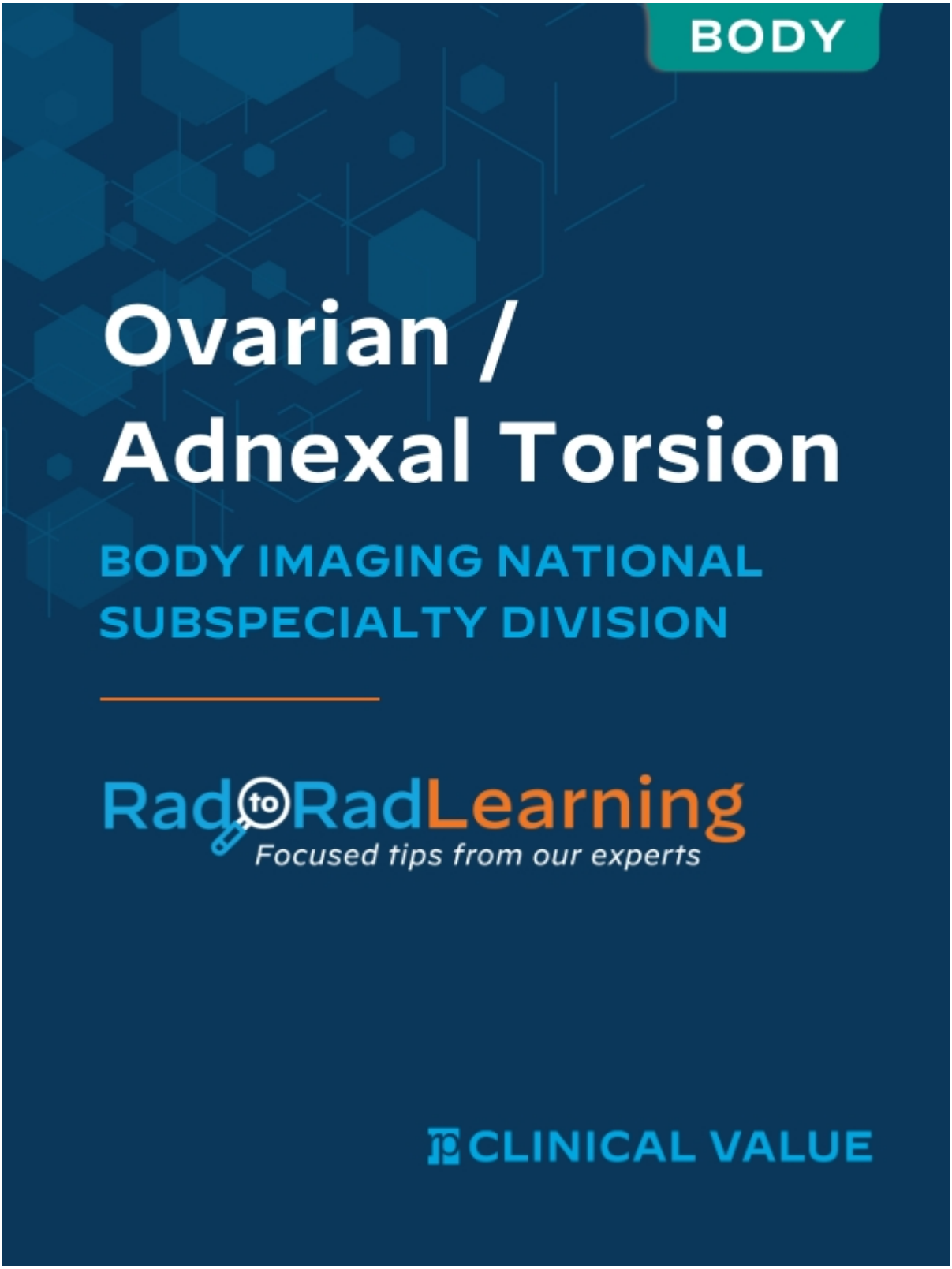


Visit the Clinical Resources page for more cases and to see what we've developed to enhance best practice recommendations, elevate image quality and patient care and update current standards throughout RP's network of practices, all to deliver excellent radiology services to patients, referring clinicians and client partners.

*Radiology Partners, through its owned and affiliated practices, is a leading physician-led and physician-owned radiology practice in the U.S. For the latest news from RP, follow us on X, LinkedIn, Instagram, YouTube and the blog.Shared to improve patient safety and healthcare delivery in the provision of radiology services. The circumstances and facts are changed, altered, or deidentified to preserve confidentiality. Privileges have not been waived.*

---

# Rad to Rad Learning: Invasive Fungal Sinusitis

## The Radiology Partners (RP) Neuroradiology National Subspecialty Division (NSD) presents our newest Rad to Rad Learning case.

The Neuroradiology NSD is part of RP's Clinical Value Team, which works to elevate patient care and enhance value through innovation, collaboration and education. To advance this goal, our radiologists and advanced practice providers are committed to sharing peer learning as valuable reminders and insights about what we encounter in our day-to-day practice.

Check back here and on X, LinkedIn and Instagram to see these common cases and our findings.




Visit the [Clinical Resources page] for more cases and to see what we've developed to enhance best practice recommendations, elevate image quality and patient care and update current standards throughout RP's network of practices, all to deliver excellent radiology services to patients, referring clinicians and client partners.

*Radiology Partners, through its owned and affiliated practices, is a leading physician-led and physician-owned radiology practice in the U.S. For the latest news from RP, follow us on X, LinkedIn, Instagram, YouTube and the blog.Shared to improve patient safety and healthcare delivery in the provision of radiology services. The circumstances and facts are changed, altered, or deidentified to preserve confidentiality. Privileges have not been waived.*