Rad to Rad Learning: Perched Facets

The Radiology Partners (RP) MSK Musculoskeletal National Subspecialty Division (NSD) presents our newest Rad to Rad Learning case.

Peer Learning Opportunity

This diagnosis is associated with high risk for spinal cord injury and vertebral artery injury.

[image_with_animation image_url="9025" image_size="large" max_width="100%" max_width_mobile="default" animation_type="entrance" animation="None" animation_movement_type="transform_y" hover_animation="none" alignment="center" border_radius="none" box_shadow="none" image_loading="default"]

Perched Facets

Malalignment of the facet joints with the inferior articular process of C5 sitting anteriorly

“perched” on the superior articular process of C6.

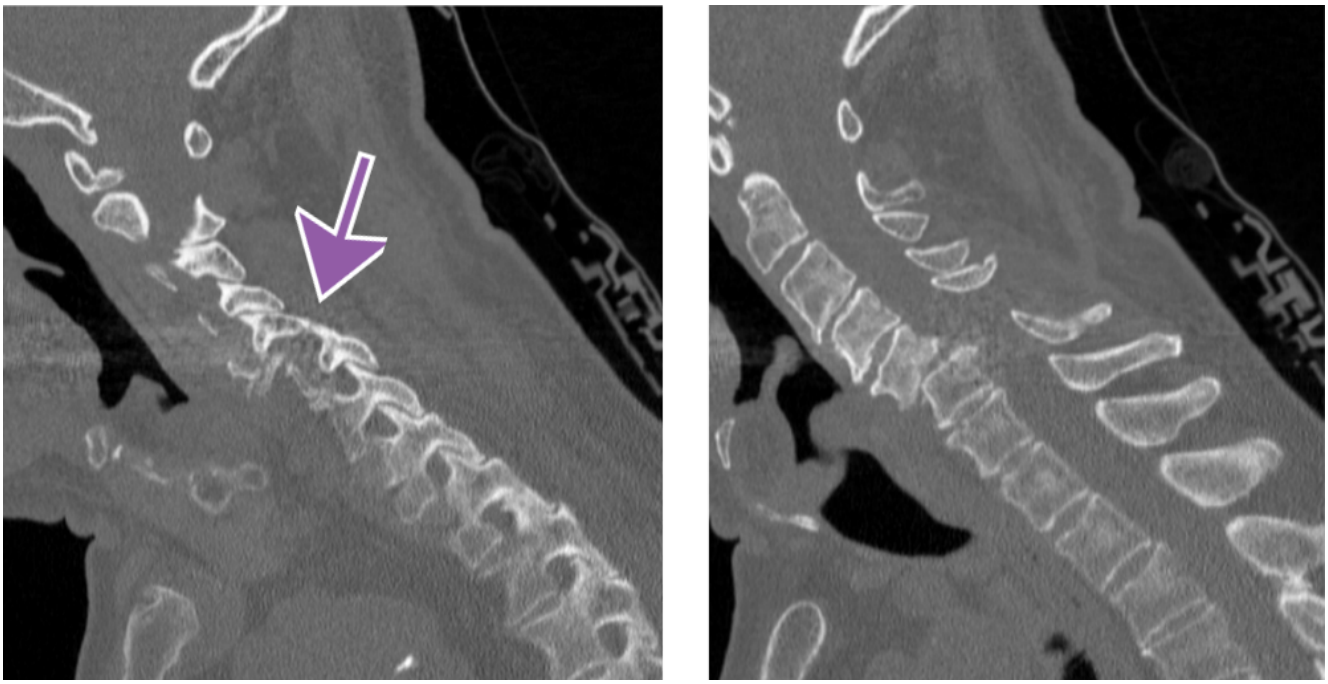

Shared to improve patient safety and healthcare delivery in the provision of radiology services. The circumstances and facts are changed, altered, or deidentified to preserve confidentiality. Privileges have not been waived.

Practical Insights

- **Mechanism matters: Due to hyperflexion, lateral compression and rotation, most often from automobile accident.**
- **Widening of the interspinous distance.**
- **Up to 90% of patients with interfacetal dislocation will present with symptoms, and up to 40% can have a complete spinal cord injury.**

Early diagnosis and treatment can decrease permanent neurologic injury incidence.

Search Pattern alert: Examine facet joints on parasagittal images.

The MSK Musculoskeletal National Subspecialty Division (NSD) is part of RP's Clinical Value Team, which works to elevate patient care and enhance value through innovation, collaboration and education. To advance this goal, our radiologists and advanced practice providers are committed to sharing peer learning as valuable reminders and insights about what we encounter in our day-to-day practice. Check back here and on X, LinkedIn and Instagram to see these common cases and our findings.

Visit the Clinical Resources page for more cases and to see what we've developed to enhance best practice recommendations, elevate image quality and patient care and update current standards throughout RP's network of practices, all to deliver excellent radiology services to patients, referring clinicians and client partners.



Radiology Partners, through its owned and affiliated practices, is a leading physician-led and physician-owned technology-enabled radiology practice in the U.S. For the

latest news from RP, follow us on X, LinkedIn, Instagram, YouTube and the blog.

Rad to Rad Learning: Hot Thyroid Nodule

The Radiology Partners (RP) NMMI Radiology National Subspecialty Division (NSD) presents our newest Rad to Rad Learning case.



Peer Learning Opportunity

On I-123 thyroid scintigraphy, focal nodular uptake is encountered frequently and is referred to as “hot nodule”.

Hot Thyroid Nodule

In this study, we see focal nodular uptake to the right thyroid gland with suppression of the remaining glandular tissue. Uptake at 24 hours is

within normal limits.



Shared to improve patient safety and healthcare delivery in the provision of radiology services. The circumstances and facts are changed, altered, or deidentified to preserve confidentiality. Privileges have not been waived.

Practical Insights

- **Nodules demonstrating focal uptake are overwhelmingly benign.**
- **Uptake of I-123 indicates that the nodule is functional and can produce thyroid hormones.**
- **Hot nodules are symptomatic in a subset of patients that have biochemical thyrotoxicosis.**
- **Symptomatic, hyperfunctioning thyroid nodules can be treated with I-131 therapy.**

Hot nodules are non-malignant and can sometimes be symptomatic.

The NMMI Radiology National Subspecialty Division (NSD) is part of RP's Clinical Value Team, which works to elevate patient care and enhance value through innovation, collaboration and education. To advance this goal, our radiologists and advanced practice providers are committed to sharing peer learning as valuable reminders and insights about what we encounter in our day-to-day practice. Check back here and on X, LinkedIn and Instagram to see these common cases and our findings.

Visit the Clinical Resources page for more cases and to see what we've developed to enhance best practice recommendations, elevate image quality and patient care and update current standards throughout RP's network of practices, all to deliver excellent radiology services to patients, referring clinicians and client partners.



Radiology Partners, through its owned and affiliated practices, is a leading physician-led and physician-owned technology-enabled radiology practice in the U.S. For the latest news from RP, follow us on X, LinkedIn, Instagram, YouTube and the blog.

Rad to Rad Learning: Portal Vein Thrombosis

The Radiology Partners (RP) National Quality and Safety Committee presents our newest Rad to Rad Learning case.

Peer Learning Opportunity

This condition will typically present with vague abdominal pain and can result in bowel ischemia, depending on extent of mesenteric vein involvement.

Portal Vein Thrombosis

Left: Bland portal vein thrombus in a non-cirrhotic patient
Right: Tumor thrombus in a patient with infiltrative hepatocellular carcinoma.

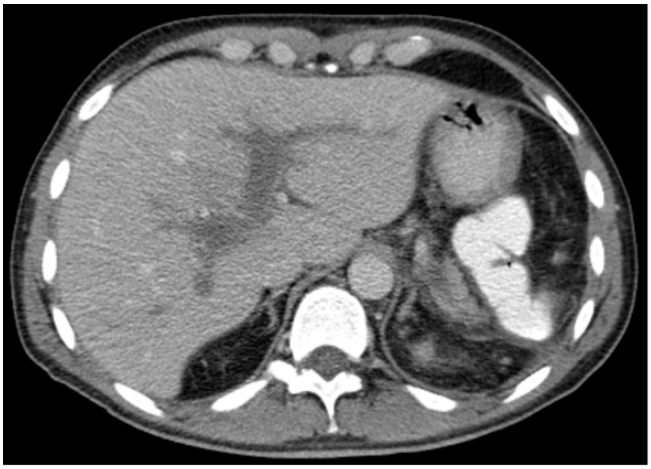
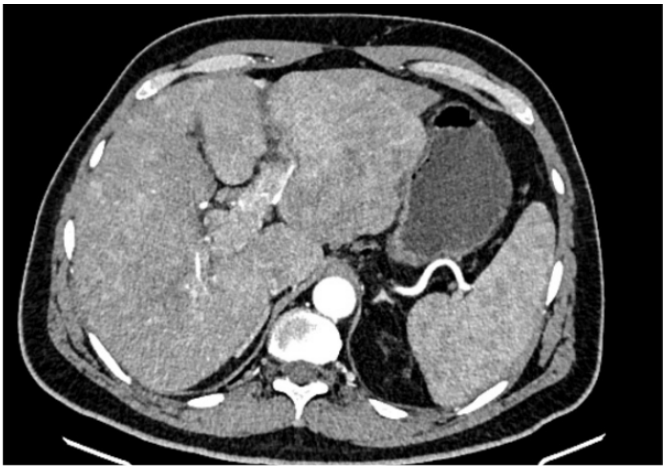

Shared to improve patient safety and healthcare delivery in the provision of radiology services. The circumstances and facts are changed, altered, or deidentified to preserve confidentiality. Privileges have not been waived.

Practical Insights

- **Most commonly seen in the setting of cirrhosis/portal hypertension resulting in slow flow. Also can be seem in hypercoagulable state.**
- **Any enhancement of the thrombus should be a clue to underlying HCC.**
- **In the chronic setting, can present as cavernous transformation with multiple serpiginous vessels feeding into both left and right portal vein branches.**

Vital to distinguish bland thrombus from tumor thrombus, which precludes possibility of liver transplant.

The RP National Quality and Safety Committee is part of RP's Clinical Value Team, which works to elevate patient care and enhance value through innovation, collaboration and education. To advance this goal, our radiologists and advanced practice providers are committed to sharing peer learning as valuable reminders and insights about what we encounter in our day-to-day practice. Check back here and on X, LinkedIn and Instagram to see these common cases and our findings.

Visit the Clinical Resources page for more cases and to see what we've developed to enhance best practice recommendations, elevate image quality and patient care and update current standards throughout RP's network of practices, all to deliver excellent radiology services to patients, referring clinicians and client partners.



Radiology Partners, through its owned and affiliated practices, is a leading physician-led and physician-owned technology-enabled radiology practice in the U.S. For the latest news from RP, follow us on X, LinkedIn, Instagram, YouTube and the blog.

Rad to Rad Learning: Wernicke Encephalopathy

The Radiology Partners (RP) Neuroradiology National Subspecialty Division (NSD) presents our newest Rad to Rad Learning case.



Peer Learning Opportunity

Up to 80% of patients with this condition suffer severe memory loss (Korsakoff syndrome) and it has a 10-20% mortality rate if untreated.

Wernicke Encephalopathy

Look for symmetric T2 hyperintensity in the medial thalami, hypothalami, mammilary bodies, and periaqueductal grey matter.

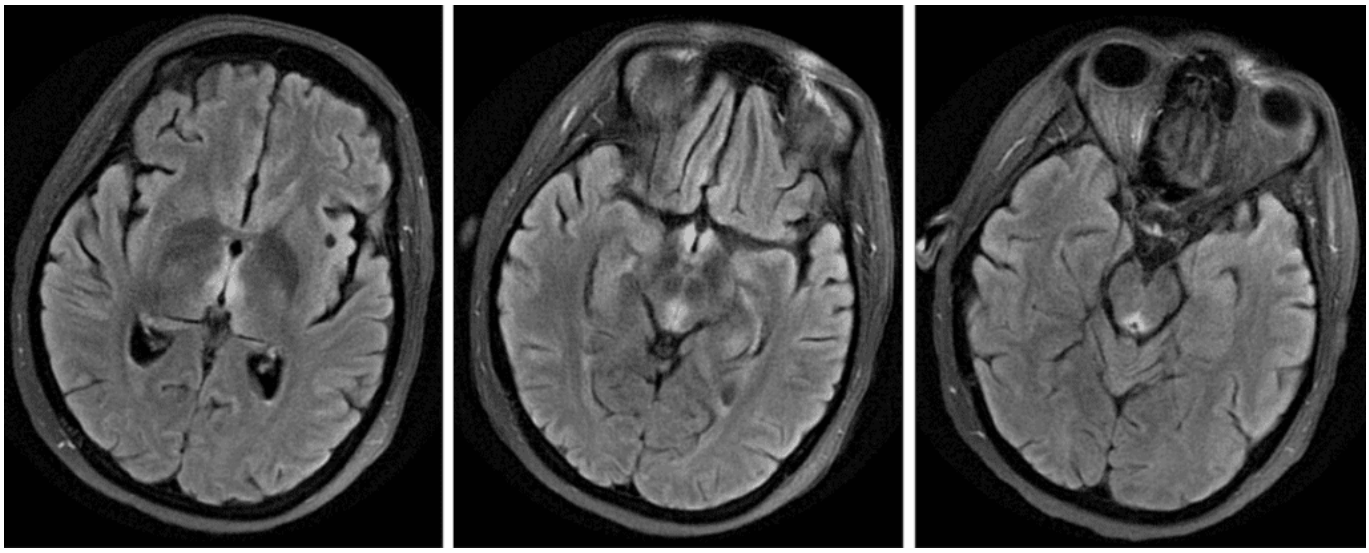

Shared to improve patient safety and healthcare delivery in the provision of radiology services. The circumstances and facts are changed, altered, or deidentified to preserve confidentiality. Privileges have not been waived.

Practical Insights

- **The classic triad of ataxia, oculomotor abnormalities and confusion is present in the majority of patients.**
- **Over 20% of thiamine deficiencies occur in nonalcoholics with malnutrition, malabsorption, prolonged vomiting, cancer, or AIDS.**
- **MRI is normal in 40% of cases.**
- **Thiamine supplementation is a cheap and effective treatment.**

🔔 Classic imaging appearance should trigger thiamine supplementation due to low-risk and high clinical impact.

The Neuroradiology National Subspecialty Division (NSD) is part of RP's Clinical Value Team, which works to elevate patient care and enhance value through innovation, collaboration and education. To advance this goal, our radiologists and advanced practice providers are committed to sharing peer learning as valuable reminders and insights about what we encounter in our day-to-day practice. Check back here and on X, LinkedIn and Instagram to see these common cases and our findings.

Visit the Clinical Resources page for more cases and to see what we've developed to enhance best practice recommendations, elevate image quality and patient care and update current standards throughout RP's network of practices, all to deliver excellent radiology services to patients, referring clinicians and client partners.



Radiology Partners, through its owned and affiliated practices, is a leading physician-led and physician-owned technology-enabled radiology practice in the U.S. For the latest news from RP, follow us on X, LinkedIn, Instagram, YouTube and the blog.

Rad to Rad Learning: Solid Pulmonary Nodules on FDG PET/CT

The Radiology Partners (RP) NMMI Radiology National Subspecialty Division (NSD) presents our newest Rad to Rad Learning case.



Peer Learning Opportunity

Low-level FDG uptake in a solid pulmonary nodule does not exclude malignancy.

Solid Pulmonary Nodules on FDG PET/CT

2018 study – Below threshold SUV. SUV max 2.2

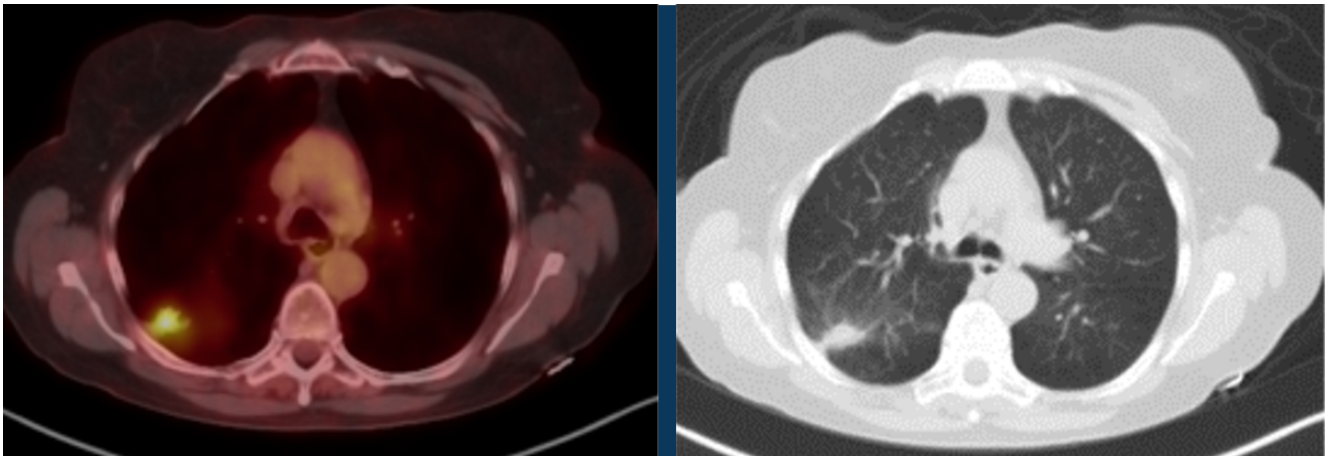

2020 study – Biopsy-proven adenocarcinoma. SUV max 5.4

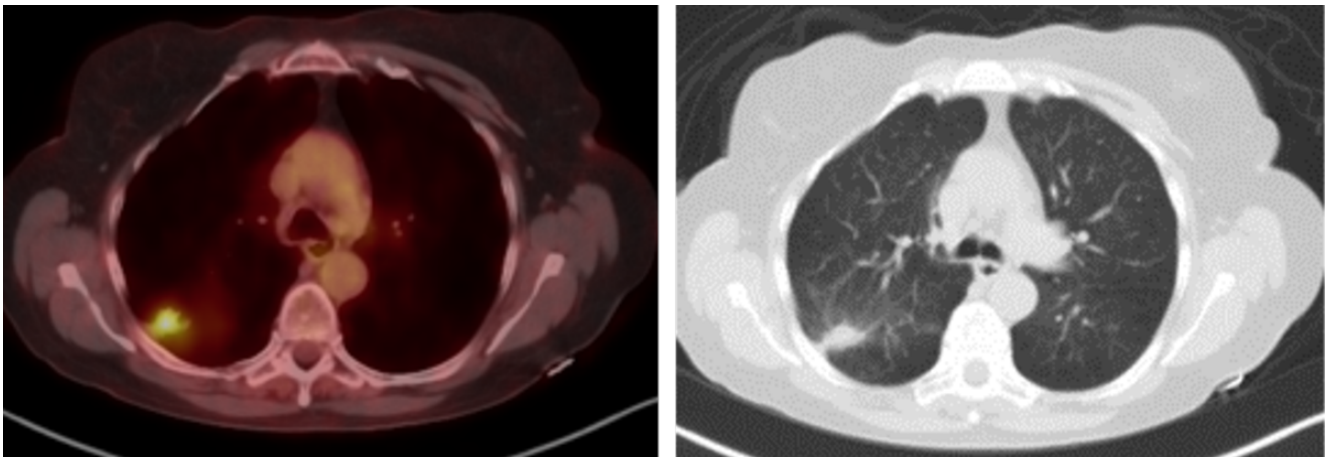

Shared to improve patient safety and healthcare delivery in the provision of radiology services. The circumstances and facts are changed, altered, or deidentified to preserve confidentiality. Privileges have not been waived.

Practical Insights

- **Historically, SUV > 2.5 has been shown to have higher positive predictive value for malignancy.**
- **However, SUV <2.5 is not definitively**

benign.

- **Nodule morphology and change over time are as important as SUV.**
- **If low FDG activity, recommend follow-up CT as a minimum**

🔔 No SUV threshold reliably differentiates malignant from benign solid nodules.

The NMMI Radiology National Subspecialty Division (NSD) is part of RP's Clinical Value Team, which works to elevate patient care and enhance value through innovation, collaboration and education. To advance this goal, our radiologists and advanced practice providers are committed to sharing peer learning as valuable reminders and insights about what we encounter in our day-to-day practice. Check back here and on X, LinkedIn and Instagram to see these common cases and our findings.

Visit the Clinical Resources page for more cases and to see what we've developed to enhance best practice recommendations, elevate image quality and patient care and update current standards throughout RP's network of practices, all to deliver excellent radiology services to patients, referring clinicians and client partners.

Radiology Partners, through its owned and affiliated practices, is a leading physician-led and physician-owned technology-enabled radiology practice in the U.S. For the latest news from RP, follow us on X, LinkedIn, Instagram, YouTube and the blog.

Rad to Rad Learning: Subsolid Pulmonary Nodules on FDG PET/CT

The Radiology Partners (RP) NMMI Radiology National Subspecialty Division (NSD) presents our newest Rad to Rad Learning case.

Peer Learning Opportunity

Low-level FDG uptake in a subsolid pulmonary nodule does not exclude malignancy.

Subsolid Pulmonary Nodules on FDG PET/CT

Feb 12, 2024 SUV max 2.1

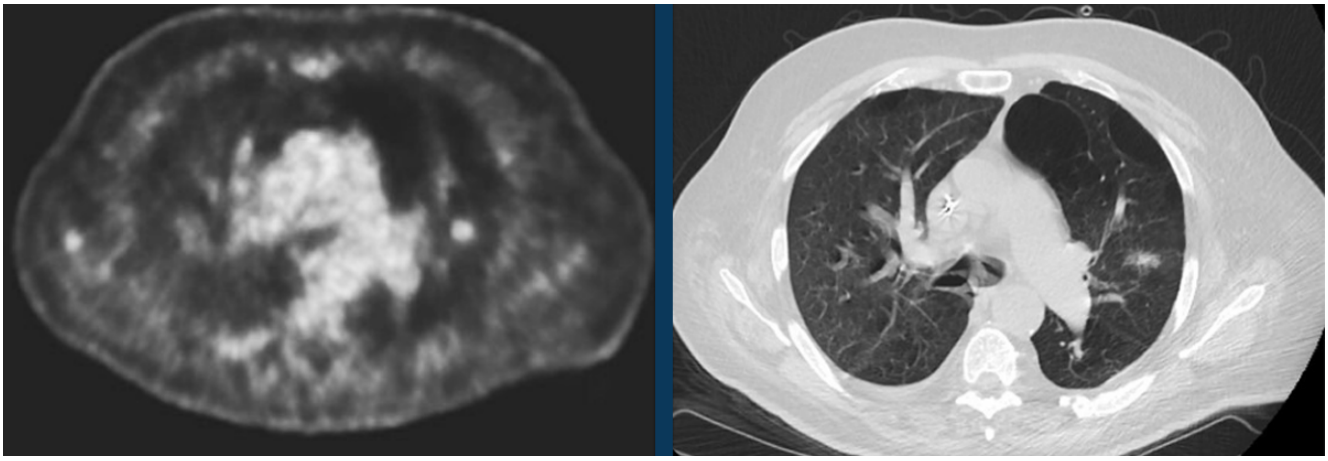

July 25, 2025. SUV max 8.2

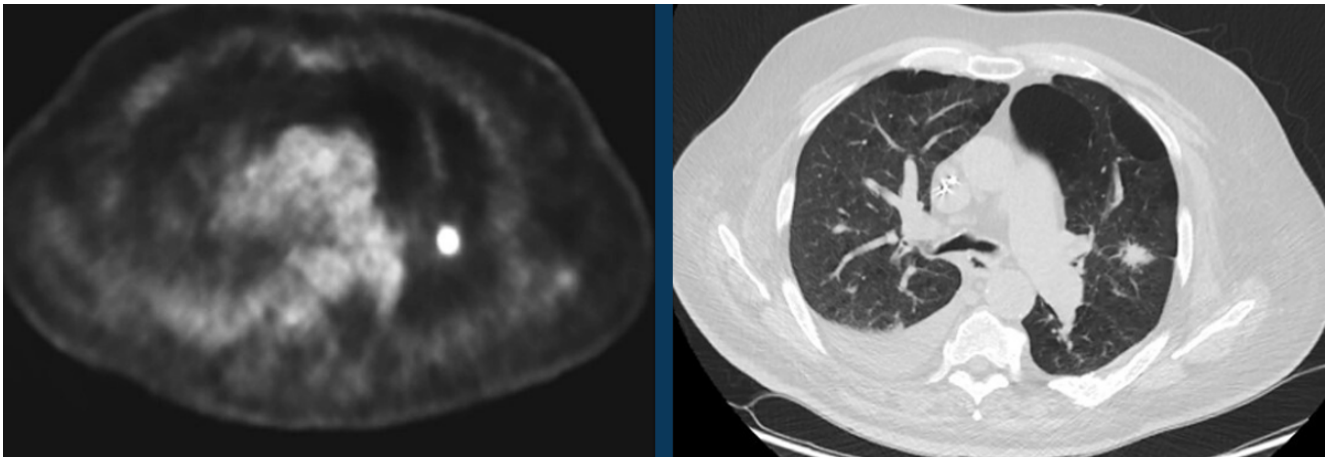

Shared to improve patient safety and healthcare delivery in the provision of radiology services. The circumstances and facts are changed, altered, or deidentified to preserve confidentiality. Privileges have not been waived.

Practical Insights

- **There are no relevant threshold values when evaluating subsolid nodules.**
- **Changes in nodule morphology over time may be as or more important than SUV max.**
- **For subsolid nodules with low SUV max, follow-up CT is recommended, unless the nodule is enlarging over time.**

Subsolid nodules with low-level FDG uptake can be malignant.

The NMMI Radiology National Subspecialty Division (NSD) is part of RP's Clinical Value Team, which works to elevate patient care and enhance value through innovation, collaboration and education. To advance this goal, our radiologists and advanced practice providers are committed to sharing peer learning as valuable reminders and insights about what we encounter in our day-to-day practice. Check back here and on X, LinkedIn and Instagram to see these common cases and our findings.

Visit the Clinical Resources page for more cases and to see what we've developed to enhance best practice recommendations, elevate image quality and patient care and update current standards throughout RP's network of practices, all to deliver excellent radiology services to patients, referring clinicians and client partners.

Radiology Partners, through its owned and affiliated practices, is a leading physician-led and physician-owned technology-enabled radiology practice in the U.S. For the latest news from RP, follow us on X, LinkedIn, Instagram, YouTube and the blog.

Rad to Rad Learning: Active GI Bleed on CTA

The Radiology Partners (RP) Interventional Radiology National Subspecialty Division (NSD) presents our newest Rad to Rad Learning case.

Peer Learning Opportunity

Higher specificity and anatomic localization of CTA enhances speed and accuracy of GI bleed diagnosis.

Active GI Bleed on CTA

Arterial extravasation that increases on delayed phase is diagnostic of active bleeding.

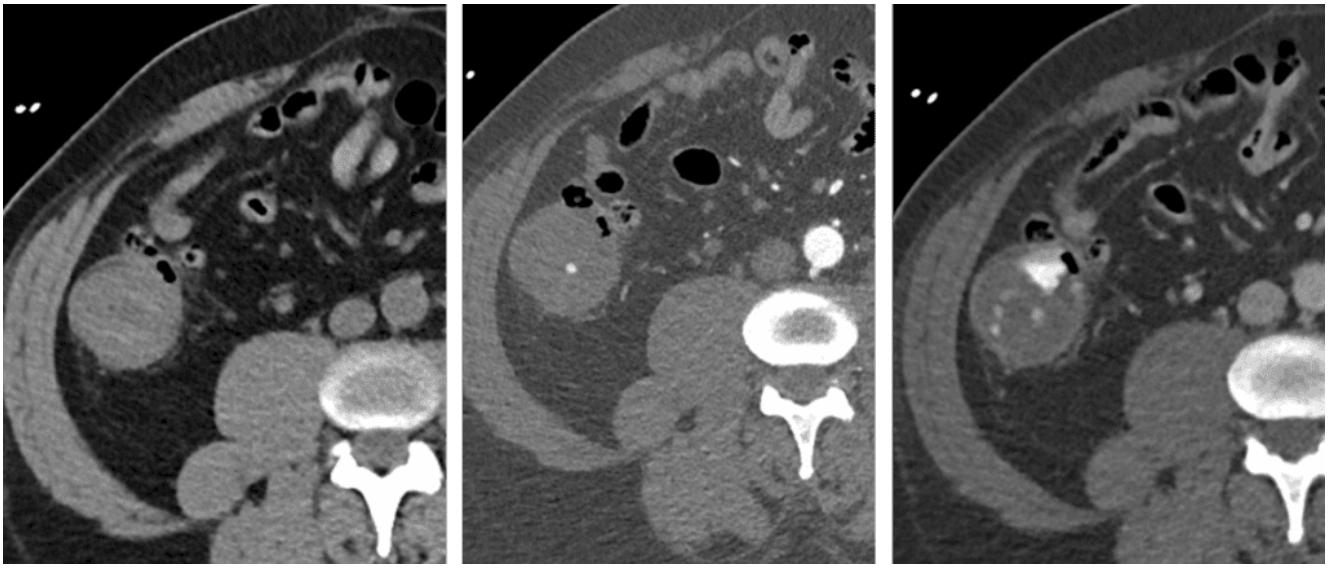

Shared to improve patient safety and healthcare delivery in the provision of radiology services. The circumstances and facts are changed, altered, or deidentified to preserve confidentiality. Privileges have not been waived.

Practical Insights

- **CTA is exam of choice to diagnose acute GI bleeding – quickly replacing tagged RBC scans.**

- **CTA protocol: No oral contrast, must include non con, arterial and venous phase imaging.**
- **Non contrast imaging is key to avoid false positives.**
- **Faster diagnosis = improved embolization success.**

🔔 Multiphase CTA = Faster, more specific, better anatomic localization.

The Interventional Radiology National Subspecialty Division (NSD) is part of RP's Clinical Value Team, which works to elevate patient care and enhance value through innovation, collaboration and education. To advance this goal, our radiologists and advanced practice providers are committed to sharing peer learning as valuable reminders and insights about what we encounter in our day-to-day practice. Check back here and on X, LinkedIn and Instagram to see these common cases and our findings.

Visit the Clinical Resources page for more cases and to see what we've developed to enhance best practice recommendations, elevate image quality and patient care and update current standards throughout RP's network of practices, all to deliver excellent radiology services to patients, referring clinicians and client partners.

Radiology Partners, through its owned and affiliated practices, is a leading physician-led and physician-owned technology-enabled radiology practice in the U.S. For the latest news from RP, follow us on X, LinkedIn, Instagram, YouTube and the blog.

Rad to Rad Learning: Male Breast Cancer

The Radiology Partners (RP) Breast Imaging National Subspecialty Division (NSD) presents our newest Rad to Rad Learning case.

Peer Learning Opportunity

While male breast cancer is rare, it is often diagnosed at a later stage with poorer outcomes.

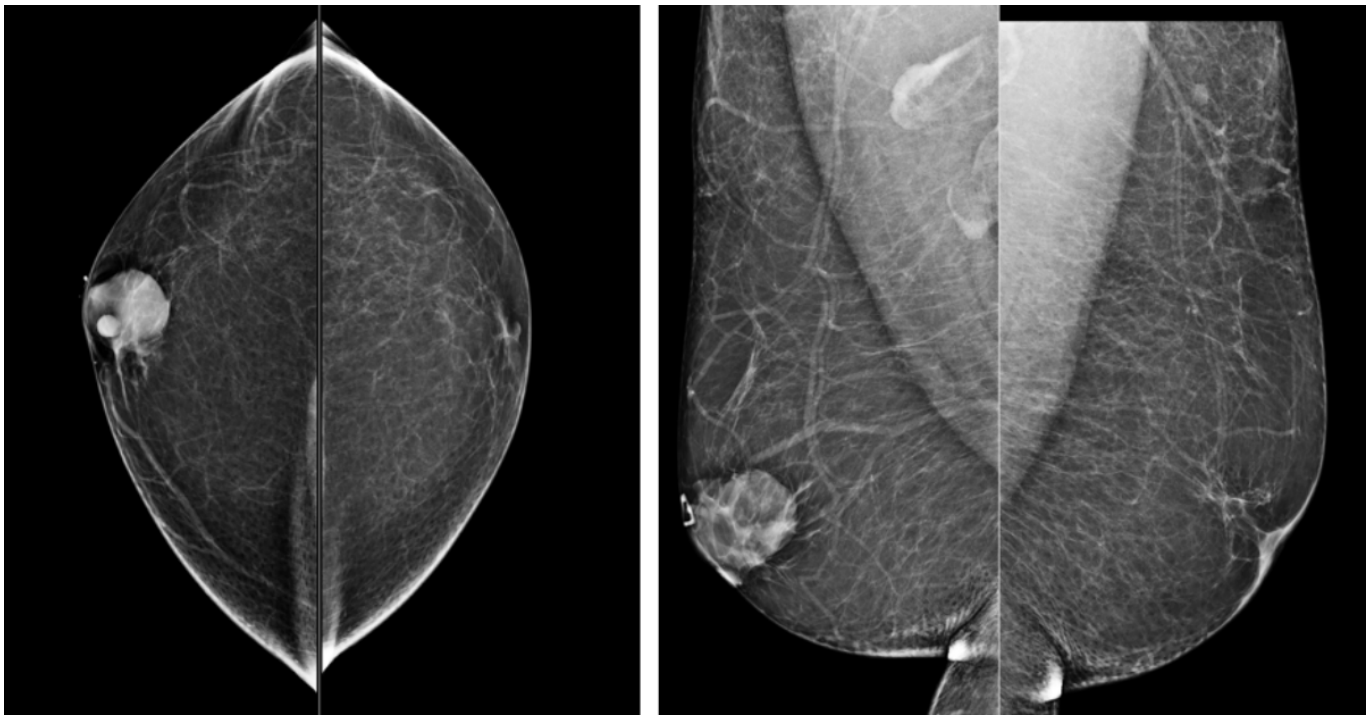

Male Breast Cancer

Most commonly found in the subareolar region, frequently with secondary signs including nipple retraction or thickening.

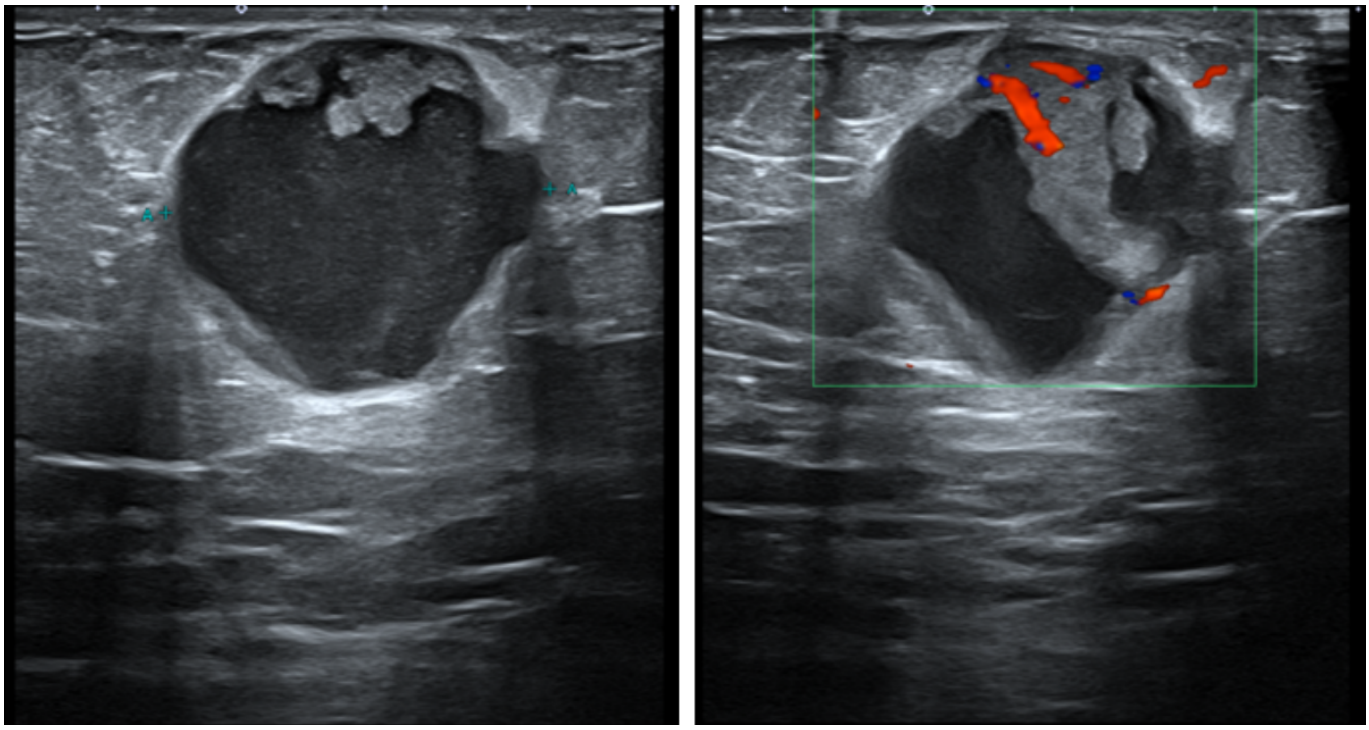

Shared to improve patient safety and healthcare delivery in the provision of radiology services. The circumstances and facts are changed, altered, or deidentified to preserve confidentiality. Privileges have not been waived.

Practical Insights

- **Gynecomastia often presents as a retroareolar, flame-shaped density that gradually blends into the surrounding fat.**
- **Can present with classic malignant features like spiculation or indistinct margins, but also as more benign-appearing oval or round shapes.**
- **Any calcification should be considered**

suspicious.

- **US typically shows a hypoechoic solid mass with variable posterior acoustic properties and often increased vascularity on Doppler.**

🔔 Always suspect malignancy if there is an irregular or spiculated retroareolar mass.

The Breast Imaging National Subspecialty Division (NSD) is part of RP's Clinical Value Team, which works to elevate patient care and enhance value through innovation, collaboration and education. To advance this goal, our radiologists and advanced practice providers are committed to sharing peer learning as valuable reminders and insights about what we encounter in our day-to-day practice. Check back here and on X, LinkedIn and Instagram to see these common cases and our findings.

Visit the Clinical Resources page for more cases and to see what we've developed to enhance best practice recommendations, elevate image quality and patient care and update current standards throughout RP's network of practices, all to deliver excellent radiology services to patients, referring clinicians and client partners.

Radiology Partners, through its owned and affiliated practices, is a leading physician-led and physician-owned technology-enabled radiology practice in the U.S. For the latest news from RP, follow us on X, LinkedIn, Instagram, YouTube and the blog.

Rad to Rad Learning: Hyperechoic Breast Lesions

The Radiology Partners (RP) Breast Imaging National Subspecialty Division (NSD) presents our newest Rad to Rad Learning case.

Peer Learning Opportunity

Hyperechogenicity is typically associated with benign breast lesions, including hamartoma, lipoma, angiolipoma, hemangioma, hematoma, fat necrosis, fibrosis, and galactocele. However, some rare malignant lesions may also appear hyperechoic.

Presents with palpable mass

Presents with new bruise

Hyperechoic Breast Lesions

Presents with persistent palpable concern

Biopsy-proven Invasive Lobular Carcinoma

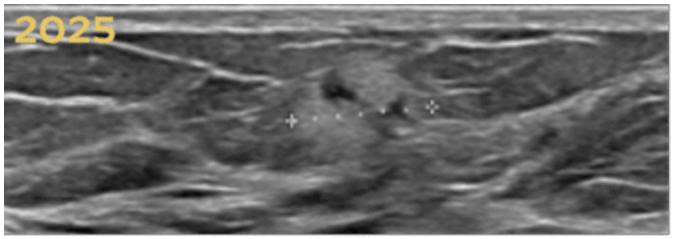

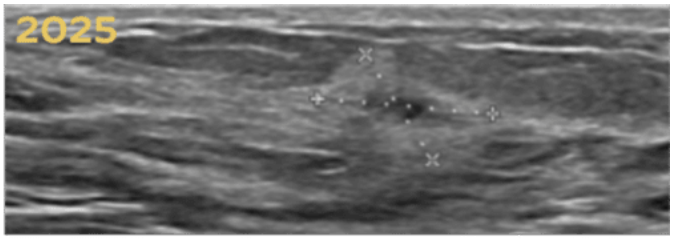

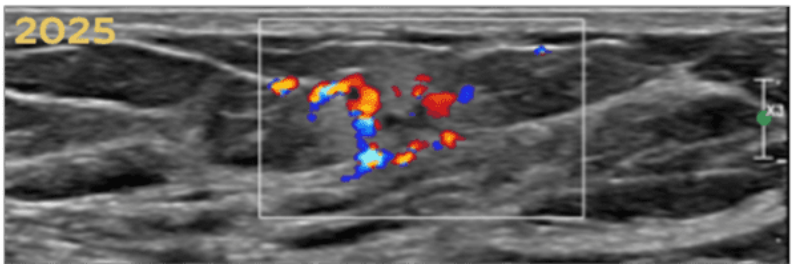

Watch for subtle, suspicious features like irregular shape, non-circumscribed margins, non-parallel orientation, or posterior acoustic shadow.

Shared to improve patient safety and healthcare delivery in the provision of radiology services. The circumstances and facts are changed, altered, or deidentified to preserve

confidentiality. Privileges have not been waived.

Practical Insights

- **Don’t dismiss a lesion simply because it is hyperechoic. Correlate US findings with other modalities and the patient’s clinical history.**
- **Consider specific histologies, not only invasive ductal or lobular carcinomas.**
- **Rare cancers like angiosarcoma, lymphoma, and metastases can also present.**
- **Don’t hesitate to recommend a biopsy for suspicious lesions. Do not rely solely on the hyperechoic appearance to rule out malignancy.**
- **Contrast-enhanced mammography is a promising alternative for dense breasts.**

Hyperechoic breast lesions are not always benign.

The Breast Imaging National Subspecialty Division (NSD) is part of RP’s Clinical Value Team, which works to elevate patient care and enhance value through innovation,

collaboration and education. To advance this goal, our radiologists and advanced practice providers are committed to sharing peer learning as valuable reminders and insights about what we encounter in our day-to-day practice. Check back here and on X, LinkedIn and Instagram to see these common cases and our findings.

Visit the Clinical Resources page for more cases and to see what we've developed to enhance best practice recommendations, elevate image quality and patient care and update current standards throughout RP's network of practices, all to deliver excellent radiology services to patients, referring clinicians and client partners.



Radiology Partners, through its owned and affiliated practices, is a leading physician-led and physician-owned technology-enabled radiology practice in the U.S. For the latest news from RP, follow us on X, LinkedIn, Instagram, YouTube and the blog.

Rad to Rad Learning: False Negative in Dense Breast

The Radiology Partners (RP) Breast Imaging National Subspecialty Division (NSD) presents our newest Rad to Rad Learning case.

Peer Learning Opportunity

Mammographic sensitivity can drop to as low as 50% in extremely dense breasts (Category D), compared to nearly 90% in fatty breasts (Category A).

Top: Screening 2021, Bottom: Screening 2024

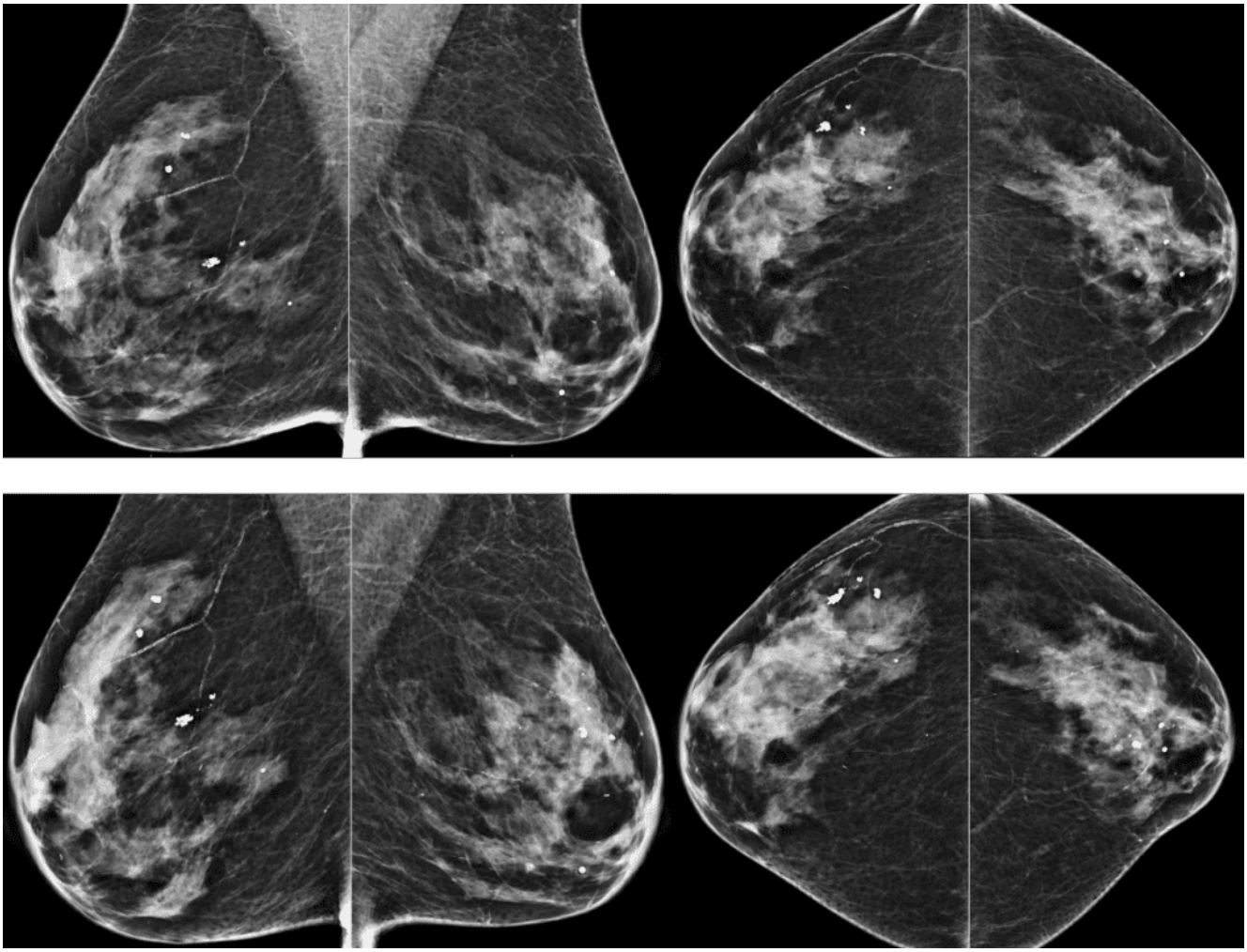

False Negative in Dense Breast

Cancers detected by supplemental screening whole-breast ultrasound are often invasive, however small and node negative, indicating they are found at an early, more treatable stage.

Post-biopsy reflector. Right breast, 7:00.

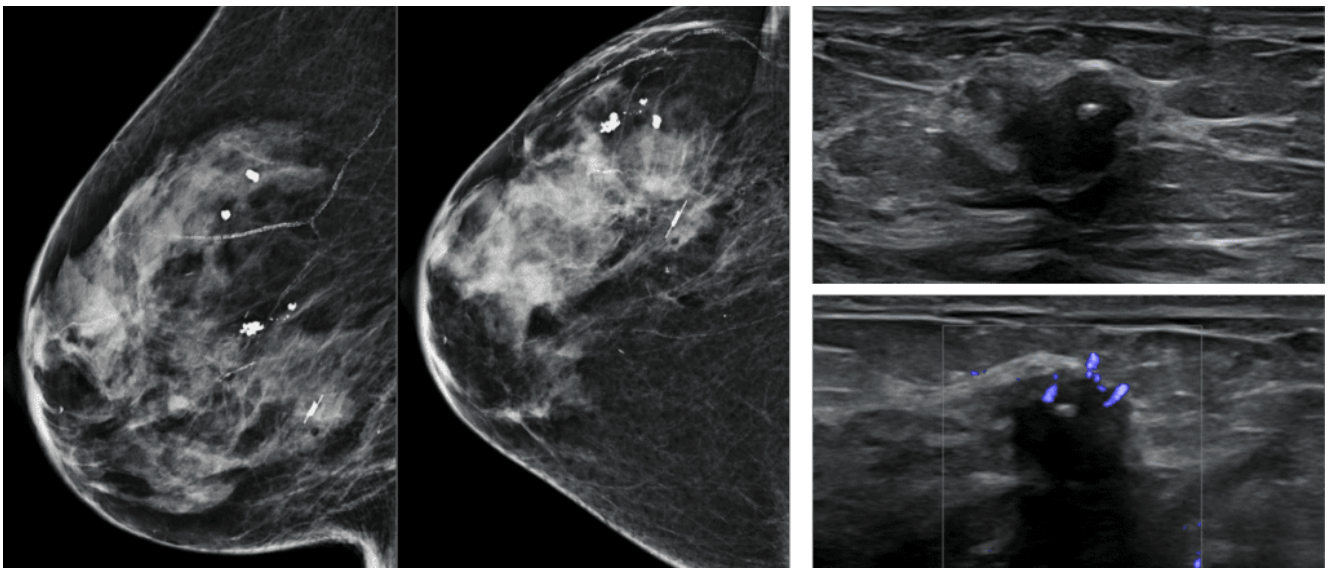

Shared to improve patient safety and healthcare delivery in the provision of radiology services. The circumstances and facts are changed, altered, or deidentified to preserve confidentiality. Privileges have not been waived.

Practical Insights

- **Breast density is an interdependent risk factor for breast cancer.**
- **Supplemental breast ultrasound can detect an additional 2-4 cancers per 1,000 women screened with dense breasts.**
- **Ultrasounds have a high false positive rate. The positive predictive value is 5-10% (compared to 25-40% for mammography).**
- **Women with dense breasts and other risk factors (e.g., strong family history,**

genetic mutations) may benefit most from supplemental MRI.

- **Contrast-enhanced mammography is a promising alternative for dense breasts.**

🔔 In dense breasts, US can find additional clinically significant cancers.

The Breast Imaging National Subspecialty Division (NSD) is part of RP's Clinical Value Team, which works to elevate patient care and enhance value through innovation, collaboration and education. To advance this goal, our radiologists and advanced practice providers are committed to sharing peer learning as valuable reminders and insights about what we encounter in our day-to-day practice. Check back here and on X, LinkedIn and Instagram to see these common cases and our findings.

Visit the Clinical Resources page for more cases and to see what we've developed to enhance best practice recommendations, elevate image quality and patient care and update current standards throughout RP's network of practices, all to deliver excellent radiology services to patients, referring clinicians and client partners.



Radiology Partners, through its owned and affiliated practices, is a leading physician-led and physician-owned technology-enabled radiology practice in the U.S. For the latest news from RP, follow us on X, LinkedIn, Instagram, YouTube and the blog.