Rad to Rad Learning: Failed Fundoplication

The Radiology Partners (RP) Body Imaging National Subspecialty Division (NSD) presents our newest Rad to Rad Learning case.

Peer Learning Opportunity

Your next case is this abdominal CT without history or priors. What is the diagnosis? Misdiagnosis may lead to ulceration, necrosis, perforation, and/or bleeding.

Patient has a recent history of fundoplication with gastric wrap around.


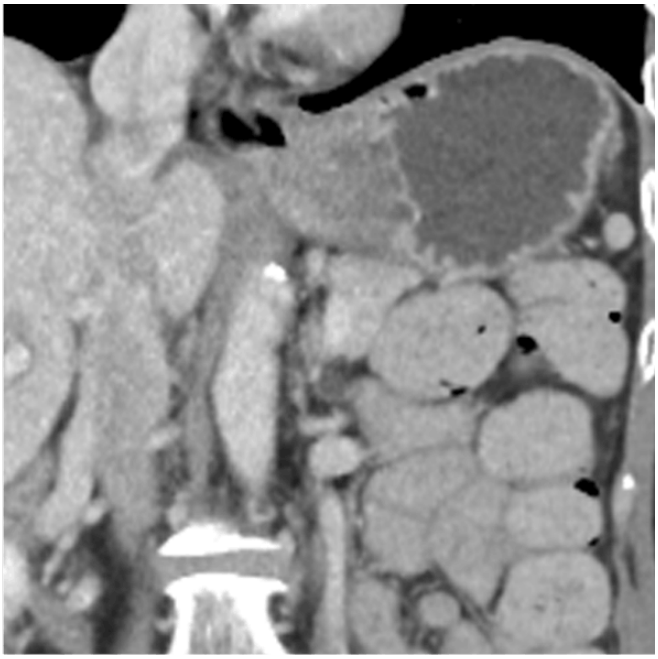

Practical Insights

- Fundoplication has a 5 year follow-up failure rate of 4-14&, with 2.8% requiring additional surgery.
- GERD, pain, and difficulty swallowing are common presenting symptoms.
- Hx of surgery is key to differentiate from GIST, adenocarcinoma, esophageal varices, gastric wall hematoma or hemorrhage.
- If there is obstruction, follow up surgery is likely required.

Takeaway: History is crucial for narrowing the differential.

*Shared to improve patient safety and healthcare delivery in the provision of radiology services. The circumstances and facts are changed, altered, or deidentified to preserve confidentiality. Privileges have not been waived.*The Body Imaging National Subspecialty Division (NSD) is part of RP's Clinical Value Team, which works to elevate patient care and enhance value through innovation, collaboration and education. To advance this goal, our radiologists and advanced practice providers are committed to sharing peer learning as valuable reminders and insights about what we encounter in our day-to-day practice. Check back here and on X, LinkedIn and Instagram to see these common cases and our findings.

Visit the Clinical Resources page for more cases and to see what we've developed to enhance best practice recommendations, elevate image quality and patient care and update current standards throughout RP's network of practices, all to deliver excellent radiology services to patients, referring clinicians and client partners.



Radiology Partners, through RP Clinical Services and its managed practices, together with Mosaic Clinical Technologies, Inc., its technology and AI division, is the leading provider of technology-enabled radiology services in the U.S., serving more than 3,400 hospitals and other healthcare facilities with high-quality radiology, technology and artificial intelligence

solutions. As a physician-led and physician-owned practice, our mission is to transform radiology by innovating across clinical value, technology, and service, while elevating the role of radiology and radiologists in healthcare. For the latest news from RP, follow us on X, LinkedIn, Instagram, YouTube and the blog.

Rad to Rad Learning: Rapid Gastric Emptying

The Radiology Partners (RP) NMMI Radiology National Subspecialty Division (NSD) presents our newest Rad to Rad Learning case.



Peer Learning Opportunity

Rapid gastric emptying and gastroparesis can both present with similar clinical symptoms. Gastric emptying examinations can definitively distinguish between the two etiologies.

1 hour: 24% retention (normal: 30-90%)

This graph displays the change in gastric activity over time at hourly intervals.

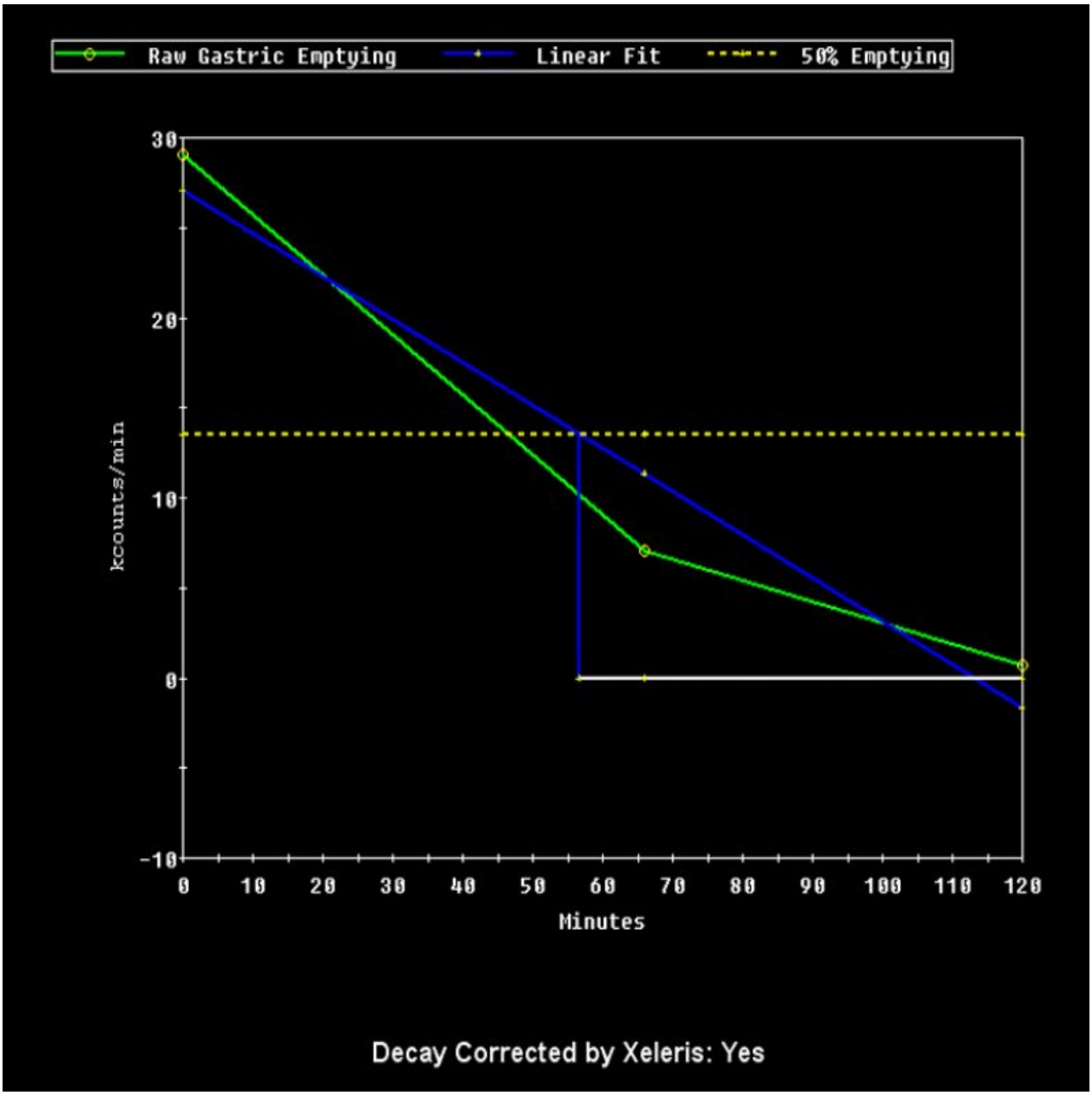

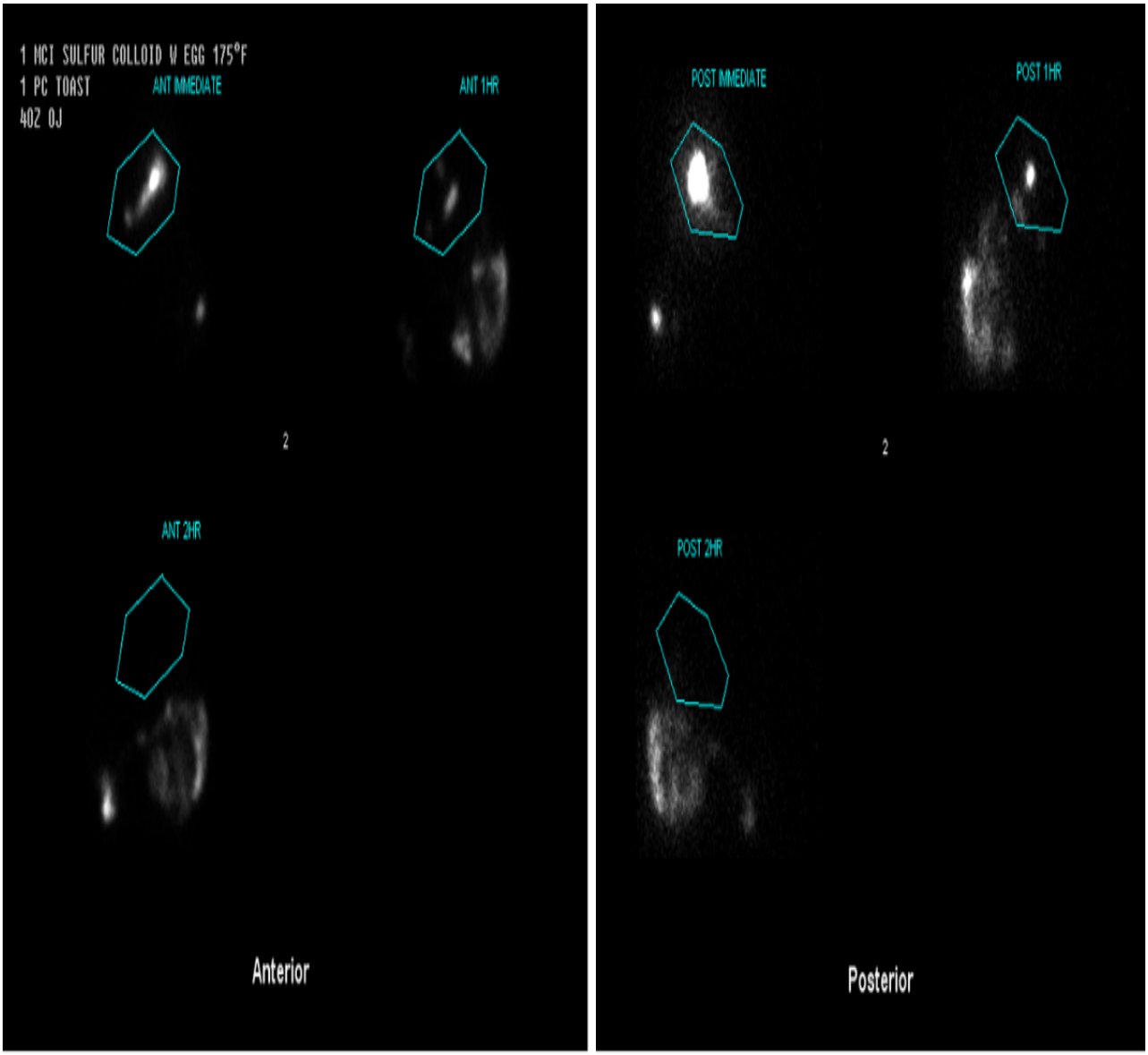

Practical Insights

- Seen frequently in patients post gastric surgery, vagotomy, and early diabetes.
- Diagnostic criteria: <30% retention at 60 minutes.

This diagnostic criteria only applies to the standard solid-phase meal, and a combination of anterior and posterior imaging.

- **This examination can be terminated at the 1 hour time point if <30% retention is seen at 60 minutes.**

🔔 Takeaway: Obtaining a detailed patient history is key to an accurate diagnosis.

*Shared to improve patient safety and healthcare delivery in the provision of radiology services. The circumstances and facts are changed, altered, or deidentified to preserve confidentiality. Privileges have not been waived.*The NMMI Radiology National Subspecialty Division (NSD) is part of RP's Clinical Value Team, which works to elevate patient care and enhance value through innovation, collaboration and education. To advance this goal, our radiologists and advanced practice providers are committed to sharing peer learning as valuable reminders and insights about what we encounter in our day-to-day practice. Check back here and on X, LinkedIn and Instagram to see these common cases and our findings.

Visit the Clinical Resources page for more cases and to see what we've developed to enhance best practice recommendations, elevate image quality and patient care and update current standards throughout RP's network of practices, all to deliver excellent radiology services to patients, referring clinicians and client partners.

-



Radiology Partners, through RP Clinical Services and its managed practices, together with Mosaic Clinical Technologies, Inc., its technology and AI division, is the leading provider of technology-enabled radiology services in the U.S., serving more than 3,400 hospitals and other healthcare facilities with high-quality radiology, technology and artificial intelligence solutions. As a physician-led and physician-owned practice, our mission is to transform radiology by innovating across clinical value, technology, and service, while elevating the role of radiology and radiologists in healthcare. For the latest news from RP, follow us on X, LinkedIn, Instagram, YouTube and the blog.

Rad to Rad Learning: Gangrenous Cholecystitis

The Radiology Partners (RP) Body Imaging National Subspecialty Division (NSD) presents our newest

Rad to Rad Learning case.

Peer Learning Opportunity

Around 2% of patients with acute cholecystitis will develop gangrenous cholecystitis, which has an elevated risk of perforation and a 22% mortality rate.

Ultrasound features include gall bladder distension measuring greater than 4 cm in short axis, wall disruption, mucosal irregularity, intraluminal membranes and pericholecystic fluid.

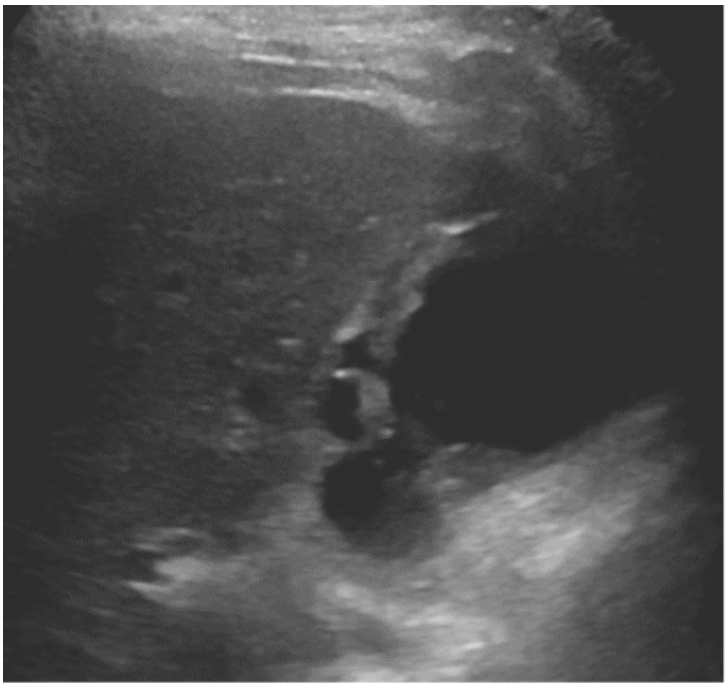

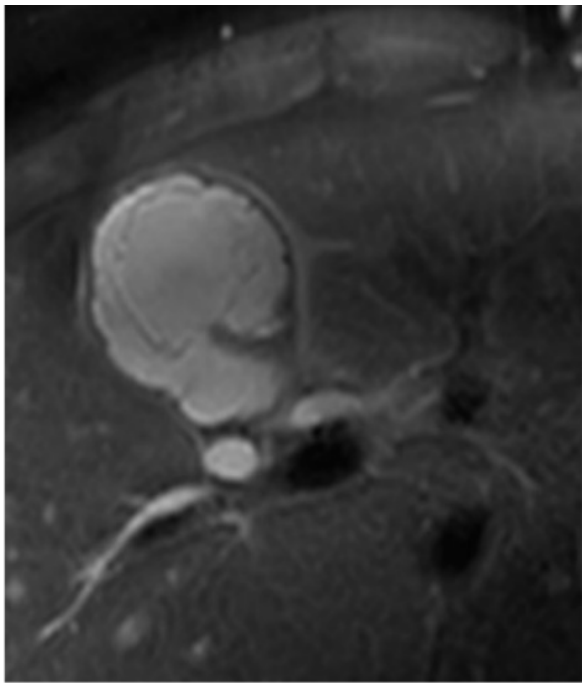

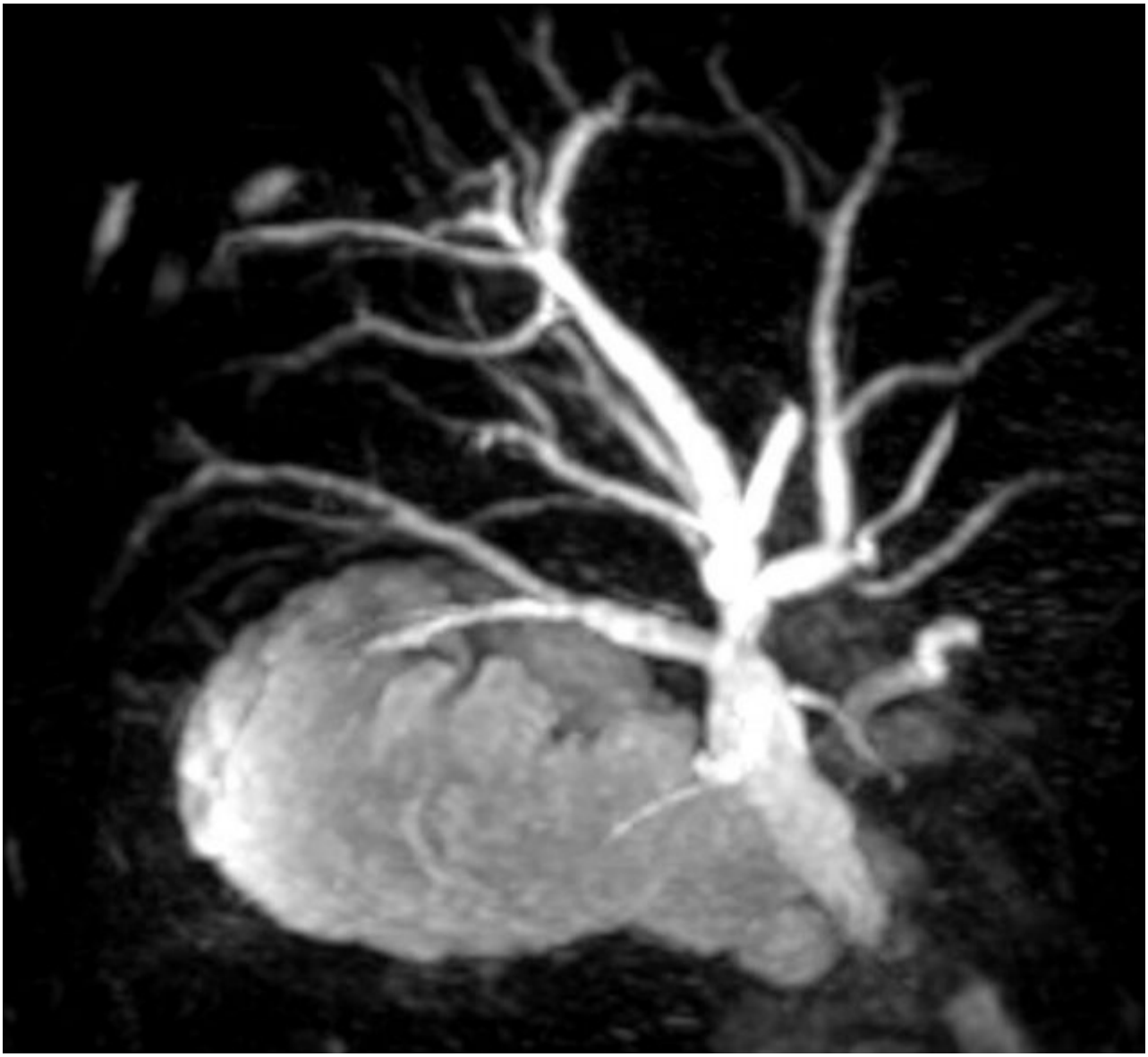

Practical Insights

- Clinical manifestations include findings of sepsis and severe right upper right quadrant pain.
- Murphy’s sign may be absent in 2/3 of patients.

Risk factors include male sex, diabetes, age >45, and cardiovascular disease.

- **Urgent cholecystectomy is the appropriate management.**

Takeaway: The hallmark is mucosal sloughing.

*Shared to improve patient safety and healthcare delivery in the provision of radiology services. The circumstances and facts are changed, altered, or deidentified to preserve confidentiality. Privileges have not been waived.*The Body Imaging National Subspecialty Division (NSD) is part of RP's Clinical Value Team, which works to elevate patient care and enhance value through innovation, collaboration and education. To advance this goal, our radiologists and advanced practice providers are committed to sharing peer learning as valuable reminders and insights about what we encounter in our day-to-day practice. Check back here and on X, LinkedIn and Instagram to see these common cases and our findings.

Visit the Clinical Resources page for more cases and to see what we've developed to enhance best practice recommendations, elevate image quality and patient care and update current standards throughout RP's network of practices, all to deliver excellent radiology services to patients, referring clinicians and client partners.

-

Radiology Partners, through its owned and affiliated practices, is a leading physician-led and physician-owned technology-enabled radiology practice in the U.S. For the latest news from RP, follow us on X, LinkedIn, Instagram, YouTube and the blog.

Rad to Rad Learning: Osteoid Osteoma

The Radiology Partners (RP) MSK National Subspecialty Division (NSD) presents our newest Rad to Rad Learning case.

Peer Learning Opportunity

Common benign bone tumors in young adults and adolescents are painful and can be radiographically occult.

Osteoid Osteoma

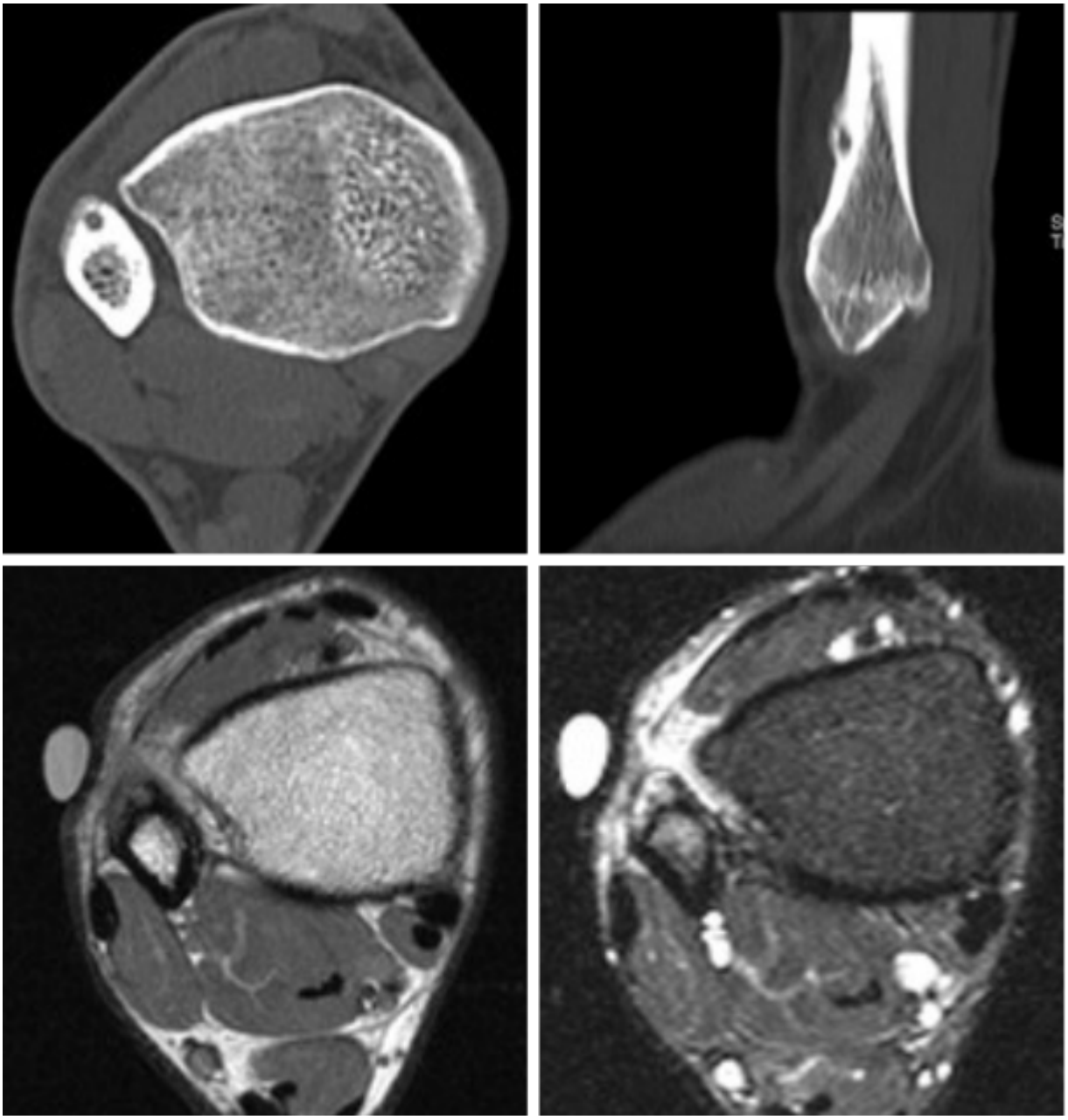

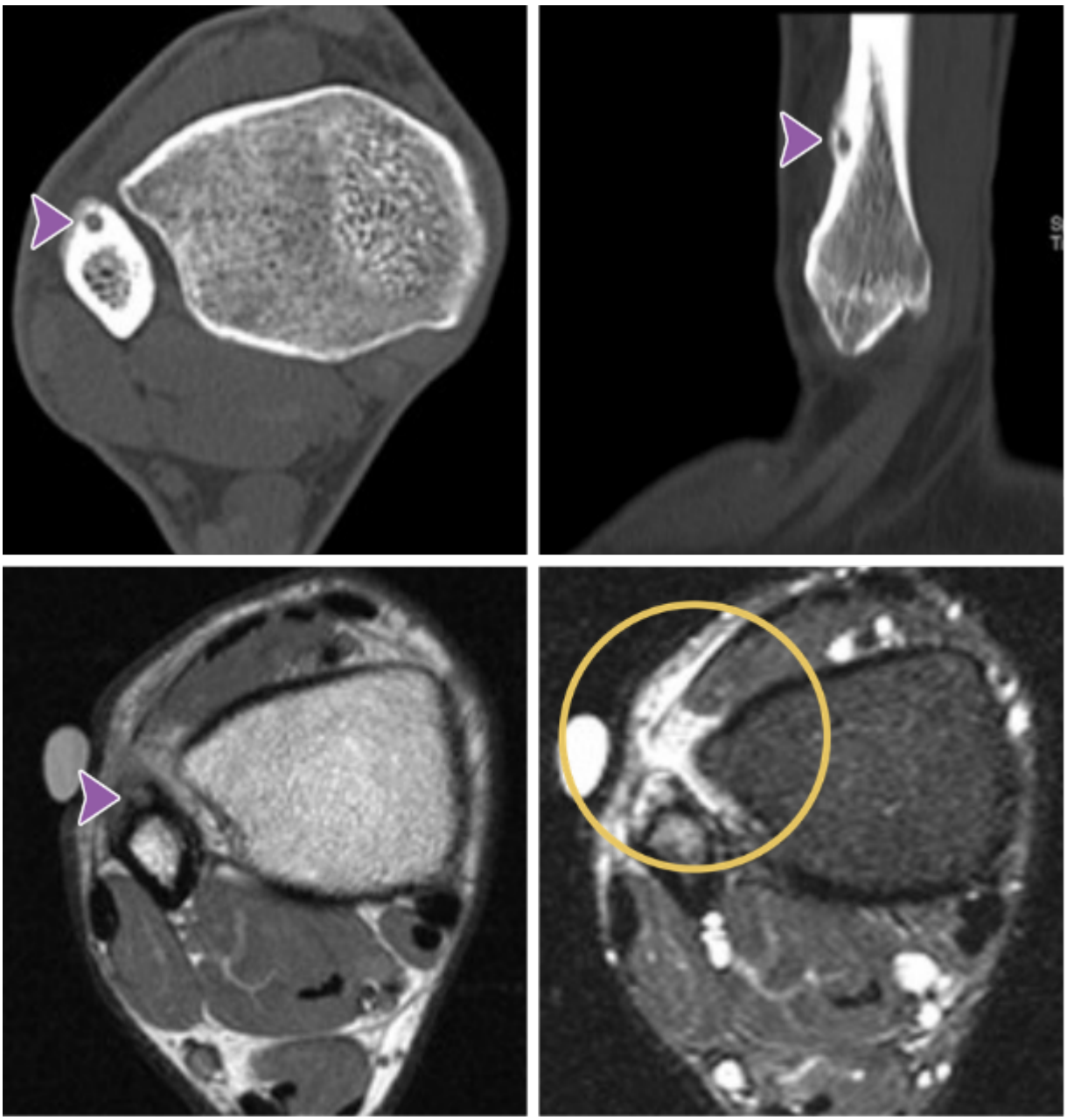

Shared to improve patient safety and healthcare delivery in the provision of radiology services. The circumstances and facts are changed, altered, or deidentified to preserve confidentiality. Privileges have not been waived.

Practical Insights

- **Cortical thickening in a young adult or**

adolescent should be on your differential.

- **More common in males.**
- **Treatment may include ablation.**
- **Look for small radiolucent nidus <2cm.**
- **Differential diagnosis should include stress fracture and infection.**
- **Presents with night pain relieved by NSAIDs.**

Takeaway: To confirm diagnosis, get a CT!

The MSK National Subspecialty Division (NSD) is part of RP's Clinical Value Team, which works to elevate patient care and enhance value through innovation, collaboration and education. To advance this goal, our radiologists and advanced practice providers are committed to sharing peer learning as valuable reminders and insights about what we encounter in our day-to-day practice. Check back here and on X, LinkedIn and Instagram to see these common cases and our findings.

Visit the Clinical Resources page for more cases and to see what we've developed to enhance best practice recommendations, elevate image quality and patient care and update current standards throughout RP's network of practices, all to deliver excellent radiology services to patients, referring clinicians and client partners.

Radiology Partners, through its owned and affiliated practices, is a leading physician-led and physician-owned technology-enabled radiology practice in the U.S. For the latest news from RP, follow us on X, LinkedIn, Instagram, YouTube and the blog.

Rad to Rad Learning: Epidural Abscess

The Radiology Partners (RP)) Neuroradiology National Subspecialty Division (NSD) presents our newest Rad to Rad Learning case.

Peer Learning Opportunity

Irreversible neurologic deficit is likely if treatment is delayed.

Typical findings are prominence of epidural soft tissue with peripheral enhancement and adjacent spondylodiscitis.

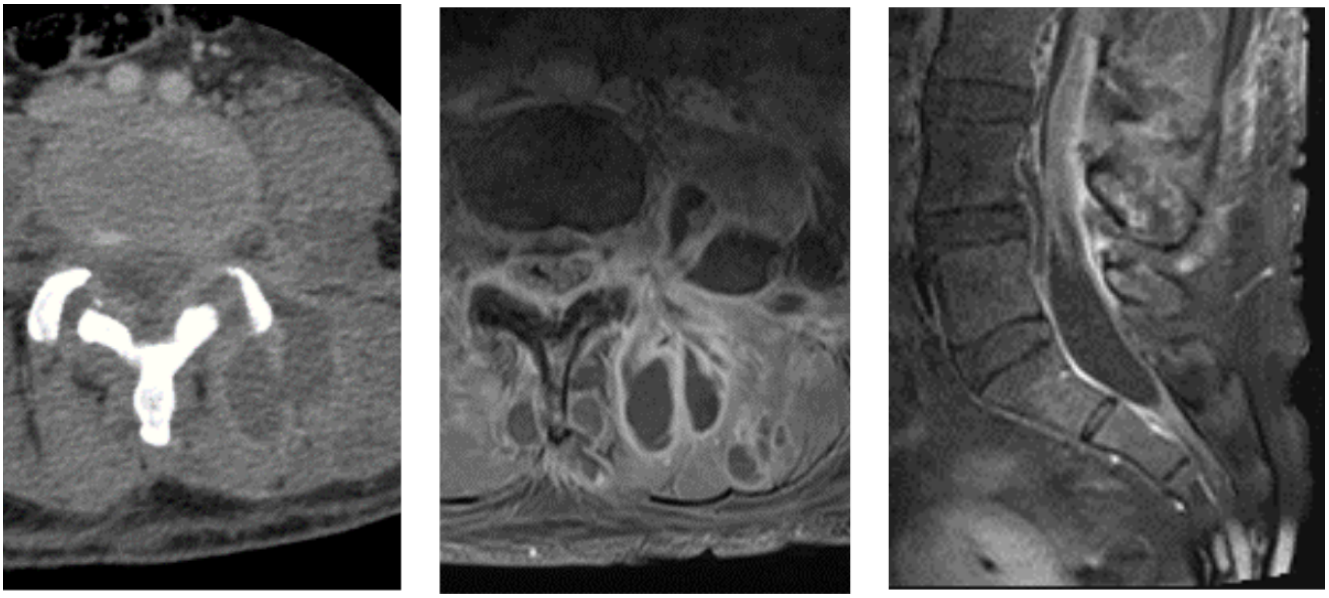

Shared to improve patient safety and healthcare delivery in the provision of radiology services. The circumstances and facts are changed, altered, or deidentified to preserve confidentiality. Privileges have not been waived.

Practical Insights

- **Predisposing factors include intravenous drug abuse, immunocompromised state, DM,**

chronic renal failure, alcoholism, cx, and other chronic illnesses.

- **The common location of epidural abscess changes from posterior above L1 to anterior below the L1.**

- **DWI can help in detection of abscesses.**

🔔 Takeaway: Epidural abscess could be seen without discitis in patients with hematogenous seeding or direct extension from a septic joint.

The Neuroradiology National Subspecialty Division (NSD) is part of RP's Clinical Value Team, which works to elevate patient care and enhance value through innovation, collaboration and education. To advance this goal, our radiologists and advanced practice providers are committed to sharing peer learning as valuable reminders and insights about what we encounter in our day-to-day practice. Check back here and on X, LinkedIn and Instagram to see these common cases and our findings.

Visit the Clinical Resources page for more cases and to see what we've developed to enhance best practice recommendations, elevate image quality and patient care and update current standards throughout RP's network of practices, all to deliver excellent radiology services to patients, referring clinicians and client partners.

Radiology Partners, through its owned and affiliated practices, is a leading physician-led and physician-owned technology-enabled radiology practice in the U.S. For the latest news from RP, follow us on X, LinkedIn, Instagram, YouTube and the blog.

Rad to Rad Learning: Increased Renal Uptake on Bone Scan

The Radiology Partners (RP) NMMI Radiology National Subspecialty Division (NSD) presents our newest Rad to Rad Learning case.

Peer Learning Opportunity

Bone scintigraphy is used in staging and restaging metastatic disease. However, it also provides information regarding renal function in oncology patients.

In the example below, osteoblastic osseous metastases are seen to the pelvic bones and left humerus. Additionally, asymmetric activity is noted to the right kidney in cortical morphology relative to the left kidney.

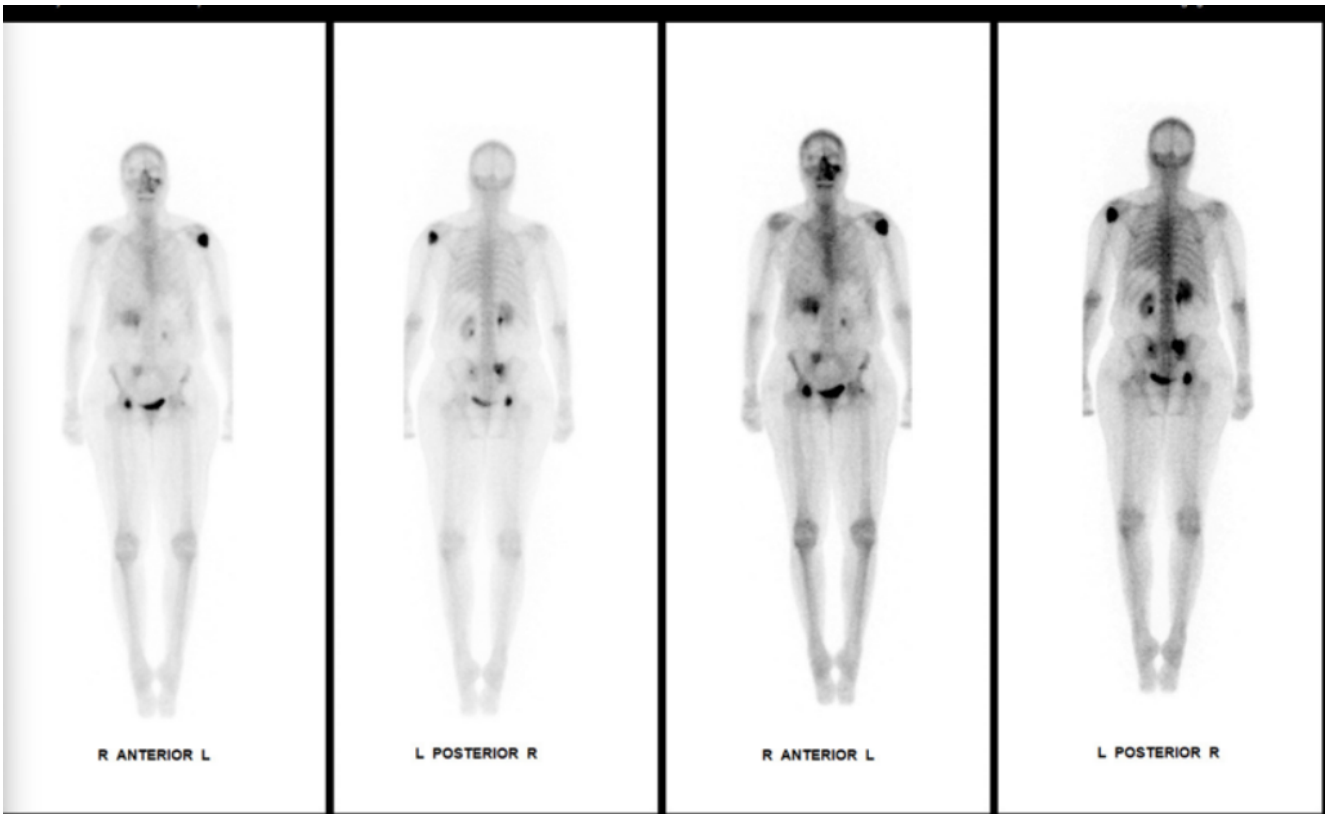

Shared to improve patient safety and healthcare delivery in the provision of radiology services. The circumstances and facts are changed, altered, or deidentified to preserve confidentiality. Privileges have not been waived.

Practical Insights

- **Asymmetric unilateral or bilateral renal uptake, also known as “Hot Kidney signs”, typically suggests underlying metabolic or systemic etiologies.**
- **The most common etiology in oncology patients is nephrotoxicity secondary to chemotherapy or other medication.**
- **Other etiologies for this finding include hypercalcemia and cirrhosis.**
- **In rare instances, increased renal uptake can be seen with aluminum breakthrough from radiotracer generator production.**

Takeaway: Bone scan provides similar physiologic information on renal function as a renogram.

The NMMI Radiology National Subspecialty Division (NSD) is part of RP’s Clinical Value Team, which works to elevate patient care and enhance value through innovation, collaboration and education. To advance this goal, our radiologists and advanced practice providers are committed to sharing peer learning as valuable reminders and insights about what we encounter in our day-to-day practice. Check back here

and on X, LinkedIn and Instagram to see these common cases and our findings.

Visit the Clinical Resources page for more cases and to see what we've developed to enhance best practice recommendations, elevate image quality and patient care and update current standards throughout RP's network of practices, all to deliver excellent radiology services to patients, referring clinicians and client partners.



Radiology Partners, through its owned and affiliated practices, is a leading physician-led and physician-owned technology-enabled radiology practice in the U.S. For the latest news from RP, follow us on X, LinkedIn, Instagram, YouTube and the blog.

Rad to Rad Learning: Fat Embolism in Sickle Cell Crisis

The Radiology Partners (RP) Neuroradiology National Subspecialty Division (NSD) presents our newest Rad to Rad Learning case.

Peer Learning Opportunity

Without typical MRI findings Cerebral Fat Embolism can be clinically misdiagnosed as a conventional large vessel stroke or seizure in SCD.

Numerous confluent white matter microinfarcts (Starfield-pattern) and petechial microhemorrhages.

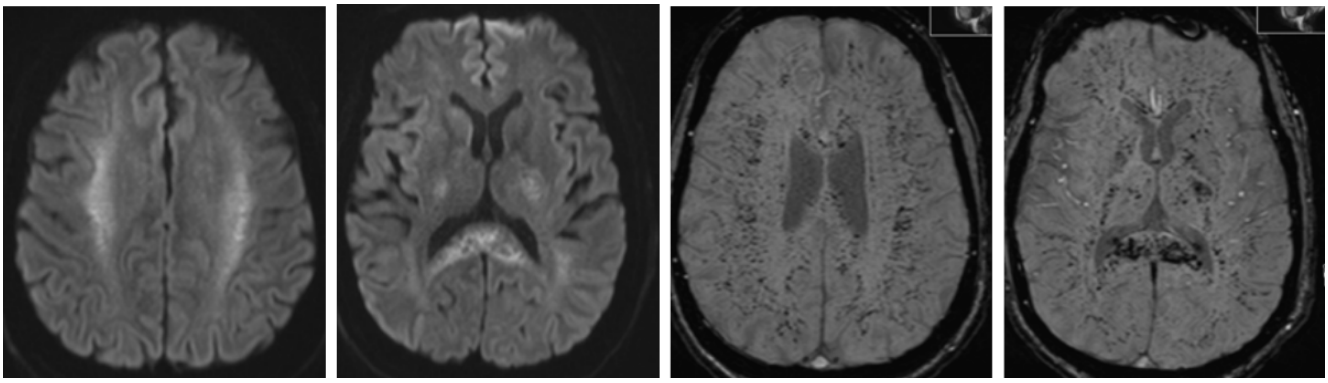

Shared to improve patient safety and healthcare delivery in the provision of radiology services. The circumstances and facts are changed, altered, or deidentified to preserve confidentiality. Privileges have not been waived.

Practical Insights

- **Occurs in <1% of Sickle Cell Disease (SCD)**
- **Fat globules released due to bone infarcts secondary to vaso-occlusion rather than fracture.**
- **History, distribution of lesions and white matter involvement differentiates from DAI and septic or cardiogenic emboli.**
- **90% of patients recover, but may develop atrophy.**

Takeaway: History and MR appearance are crucial for diagnosis.

The Neuroradiology National Subspecialty Division (NSD) is part of RP's Clinical Value Team, which works to elevate patient care and enhance value through innovation, collaboration and education. To advance this goal, our radiologists and advanced practice providers are committed to sharing peer learning as valuable reminders and insights about what we encounter in our day-to-day practice. Check back here and on X, LinkedIn and Instagram to see these common cases and our findings.

Visit the Clinical Resources page for more cases and to see

what we've developed to enhance best practice recommendations, elevate image quality and patient care and update current standards throughout RP's network of practices, all to deliver excellent radiology services to patients, referring clinicians and client partners.



Radiology Partners, through its owned and affiliated practices, is a leading physician-led and physician-owned technology-enabled radiology practice in the U.S. For the latest news from RP, follow us on X, LinkedIn, Instagram, YouTube and the blog.

Rad to Rad Learning: High-Risk Aortic Dissection

The Radiology Partners (RP) Interventional Radiology National Subspecialty Division (NSD) presents our newest Rad to

Rad Learning case.

Peer Learning Opportunity

High-risk features should be identified and described to direct management (surgical, endovascular, or hybrid).

Report true / false lumen extension into coronaries, arch vessels, and visceral arteries.

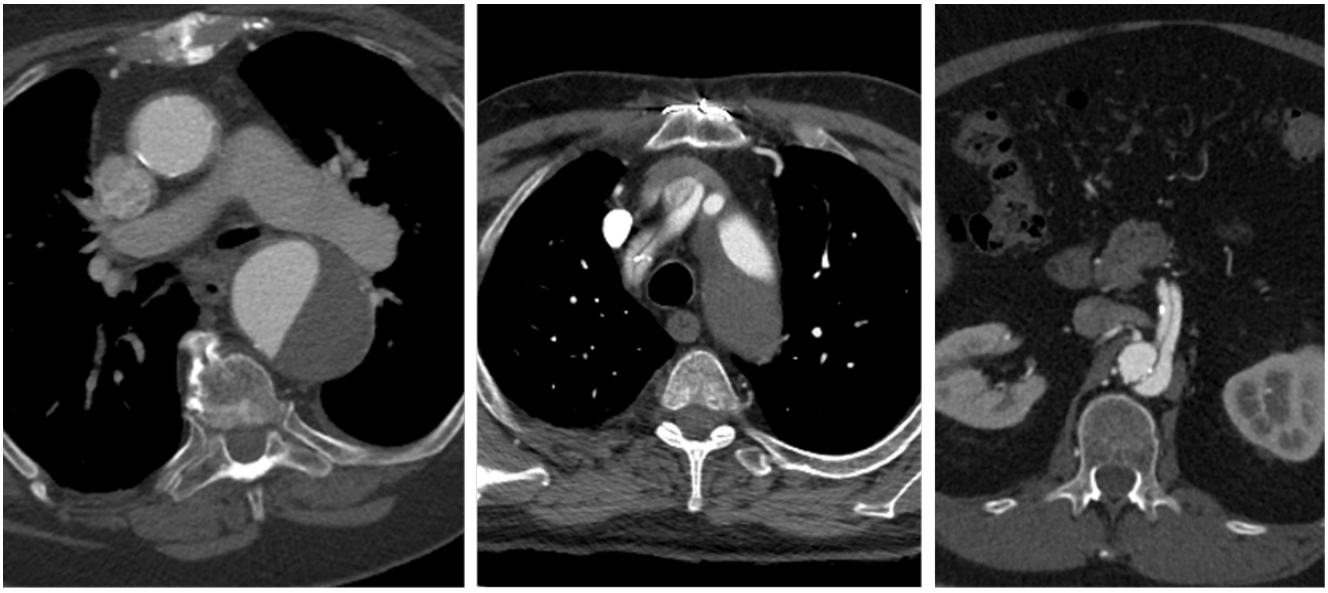

Shared to improve patient safety and healthcare delivery in the provision of radiology services. The circumstances and facts are changed, altered, or deidentified to preserve confidentiality. Privileges have not been waived.

Practical Insights

High Risk Features:

- **Hemothorax / hemopericardium.**
- **End organ infarction.**
- **Aortic diameter >40mm, false lumen diameter >22mm.**
- **Entry tear on the lesser curvature of the aorta.**
- **Refractory pain and/or hypertension.**

Takeaway: Accurate characterization of dissections improves survival.

The Interventional Radiology National Subspecialty Division (NSD) is part of RP's Clinical Value Team, which works to elevate patient care and enhance value through innovation, collaboration and education. To advance this goal, our radiologists and advanced practice providers are committed to sharing peer learning as valuable reminders and insights about what we encounter in our day-to-day practice. Check back here and on X, LinkedIn and Instagram to see these common cases and our findings.

Visit the Clinical Resources page for more cases and to see what we've developed to enhance best practice recommendations,

elevate image quality and patient care and update current standards throughout RP's network of practices, all to deliver excellent radiology services to patients, referring clinicians and client partners.

Radiology Partners, through its owned and affiliated practices, is a leading physician-led and physician-owned technology-enabled radiology practice in the U.S. For the latest news from RP, follow us on X, LinkedIn, Instagram, YouTube and the blog.

Rad to Rad Learning: Cavernous Sinus Hemangioma

The Radiology Partners (RP) Neuroradiology National Subspecialty Division (NSD) presents our newest Rad to Rad

Learning case.

Peer Learning Opportunity

High risk of intraoperative hemorrhage with over 10% mortality rate if surgical removal is attempted.

Typical findings are well-defined, homogeneous, markedly T2 hyperintense, avidly enhancing cavernous sinus lesion.

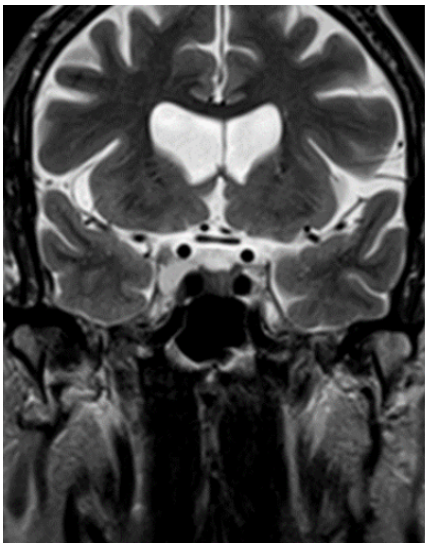
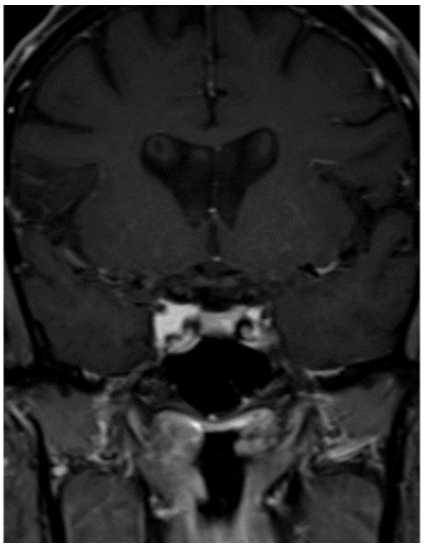


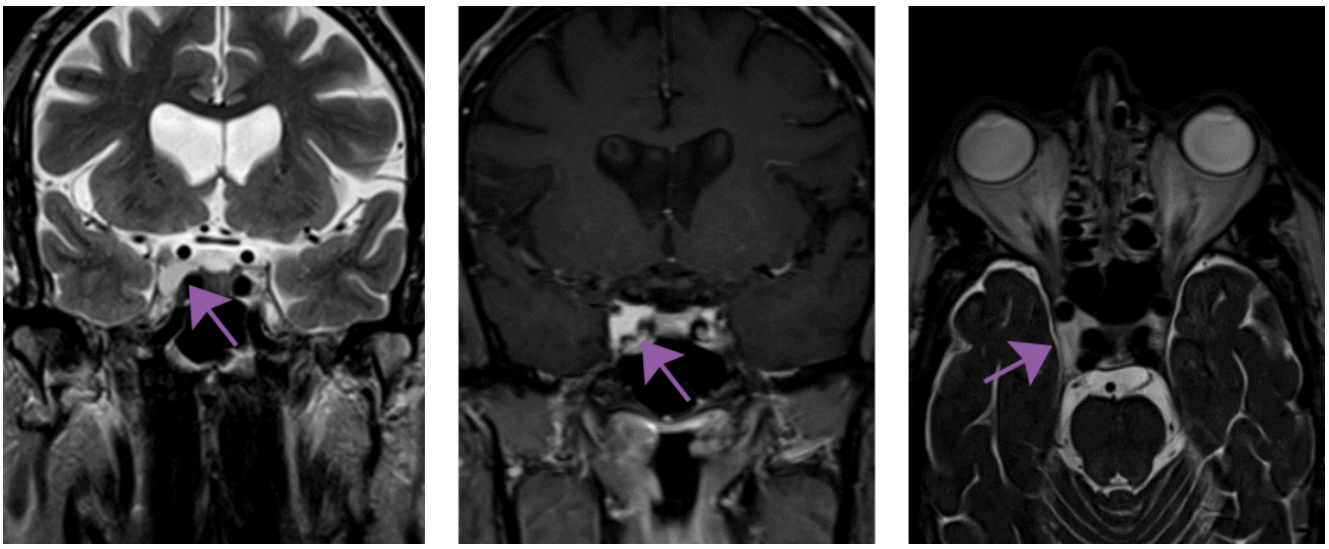

Shared to improve patient safety and healthcare delivery in the provision of radiology services. The circumstances and facts are changed, altered, or deidentified to preserve confidentiality. Privileges have not been waived.

Practical Insights

- **Marked T2 hyperintensity, vascular encasement, progressive “filling-in”, vascular blush, or the absence of hyperostosis, vascular narrowing, or connection to the pituitary gland differentiates it from meningioma, adenoma, schwannoma, or metastasis.**

Takeaway: : Pre-treatment diagnosis is critical since lesion is radiosensitive, but surgically

challenging.

The Neuroradiology National Subspecialty Division (NSD)) is part of RP's Clinical Value Team, which works to elevate patient care and enhance value through innovation, collaboration and education. To advance this goal, our radiologists and advanced practice providers are committed to sharing peer learning as valuable reminders and insights about what we encounter in our day-to-day practice. Check back here and on X, LinkedIn and Instagram to see these common cases and our findings.

Visit the Clinical Resources page for more cases and to see what we've developed to enhance best practice recommendations, elevate image quality and patient care and update current standards throughout RP's network of practices, all to deliver excellent radiology services to patients, referring clinicians and client partners.



Radiology Partners, through its owned and affiliated practices, is a leading physician-led and physician-owned technology-enabled radiology practice in the U.S. For the latest news from RP, follow us on X, LinkedIn, Instagram, YouTube and the blog.

Rad to Rad Learning: Perforated Pacer Lead

The Radiology Partners (RP) Cardiothoracic Imaging National Subspecialty Division (NSD) presents our newest Rad to Rad Learning case.

Peer Learning Opportunity

This patient has a normally functioning pacemaker, but where is the tip of this pacer lead?

Artifacts present in standard axial views can make it difficult to localalize the tips of pacer leads. Oblique MPRs should be used to clarify positioning.



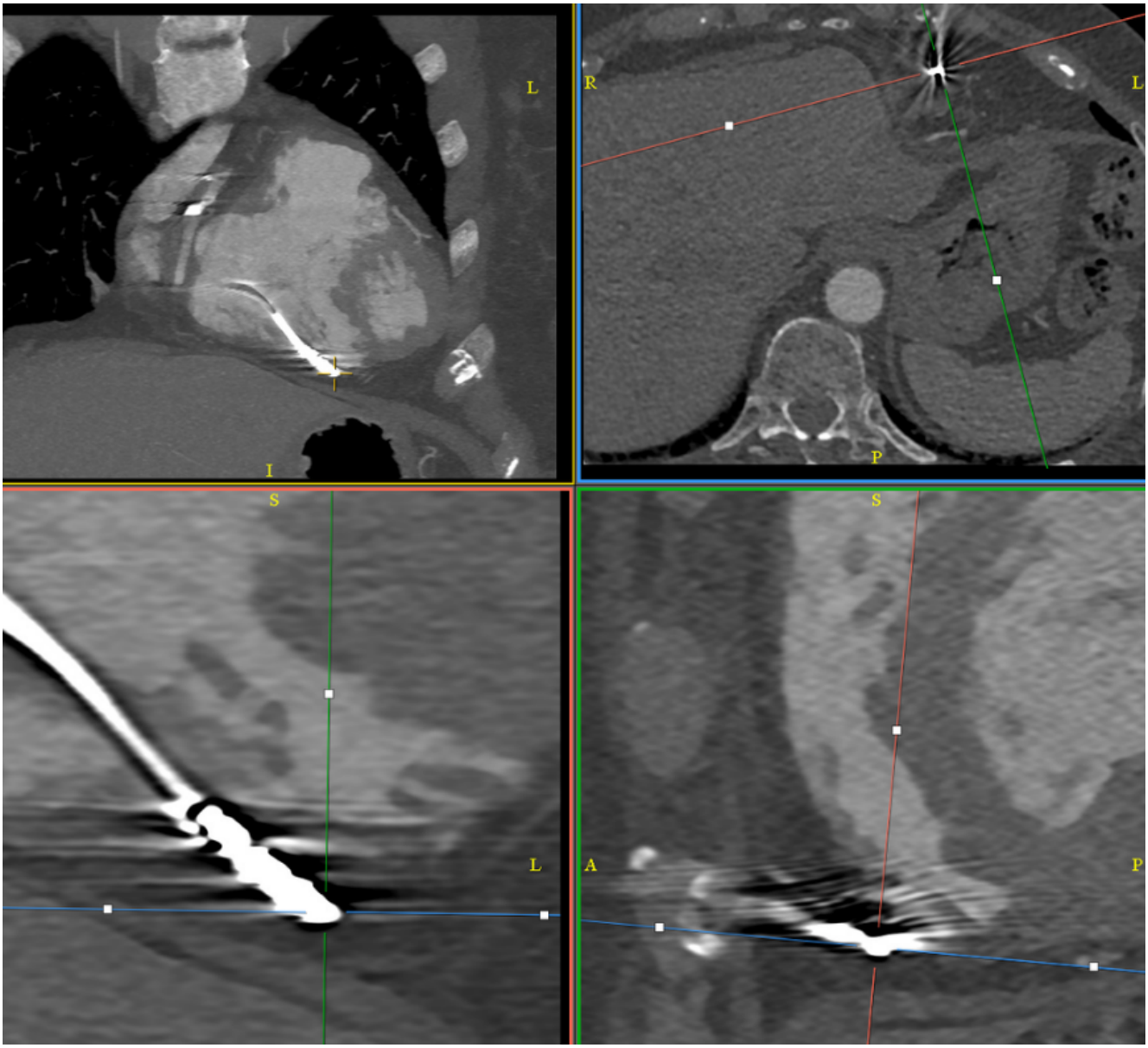

Shared to improve patient safety and healthcare delivery in the provision of radiology services. The circumstances and facts are changed, altered, or deidentified to preserve confidentiality. Privileges have not been waived.

Practical Insights

- **Even though pacer lead complications are rare, pacemakers are common devices.**

- **Devices may be functional even with perforation, but may result in complications on attempted lead placement.**

🔔 Takeaway: Lead perforation may not be clinically evident, but can be detected by imaging.

The Cardiothoracic Imaging National Subspecialty Division (NSD) is part of RP's Clinical Value Team, which works to elevate patient care and enhance value through innovation, collaboration and education. To advance this goal, our radiologists and advanced practice providers are committed to sharing peer learning as valuable reminders and insights about what we encounter in our day-to-day practice. Check back here and on X, LinkedIn and Instagram to see these common cases and our findings.

Visit the Clinical Resources page for more cases and to see what we've developed to enhance best practice recommendations, elevate image quality and patient care and update current standards throughout RP's network of practices, all to deliver excellent radiology services to patients, referring clinicians and client partners.



Radiology Partners, through its owned and affiliated practices, is a leading physician-led and physician-owned technology-enabled radiology practice in the U.S. For the latest news from RP, follow us on X, LinkedIn, Instagram, YouTube and the blog.