Rad to Rad Learning: Cardiac Device Complications

The Radiology Partners (RP) Cardiothoracic Imaging National Subspecialty Division (NSD) presents our newest Rad to Rad Learning case.

Peer Learning Opportunity

How many TAVRs?

History is two valve-in-valve TAVR implant redos for a total of 3 implants. Two of the implants (yellow arrows) have embolized into the ascending aorta, with the original (purple arrow) still in normal position.

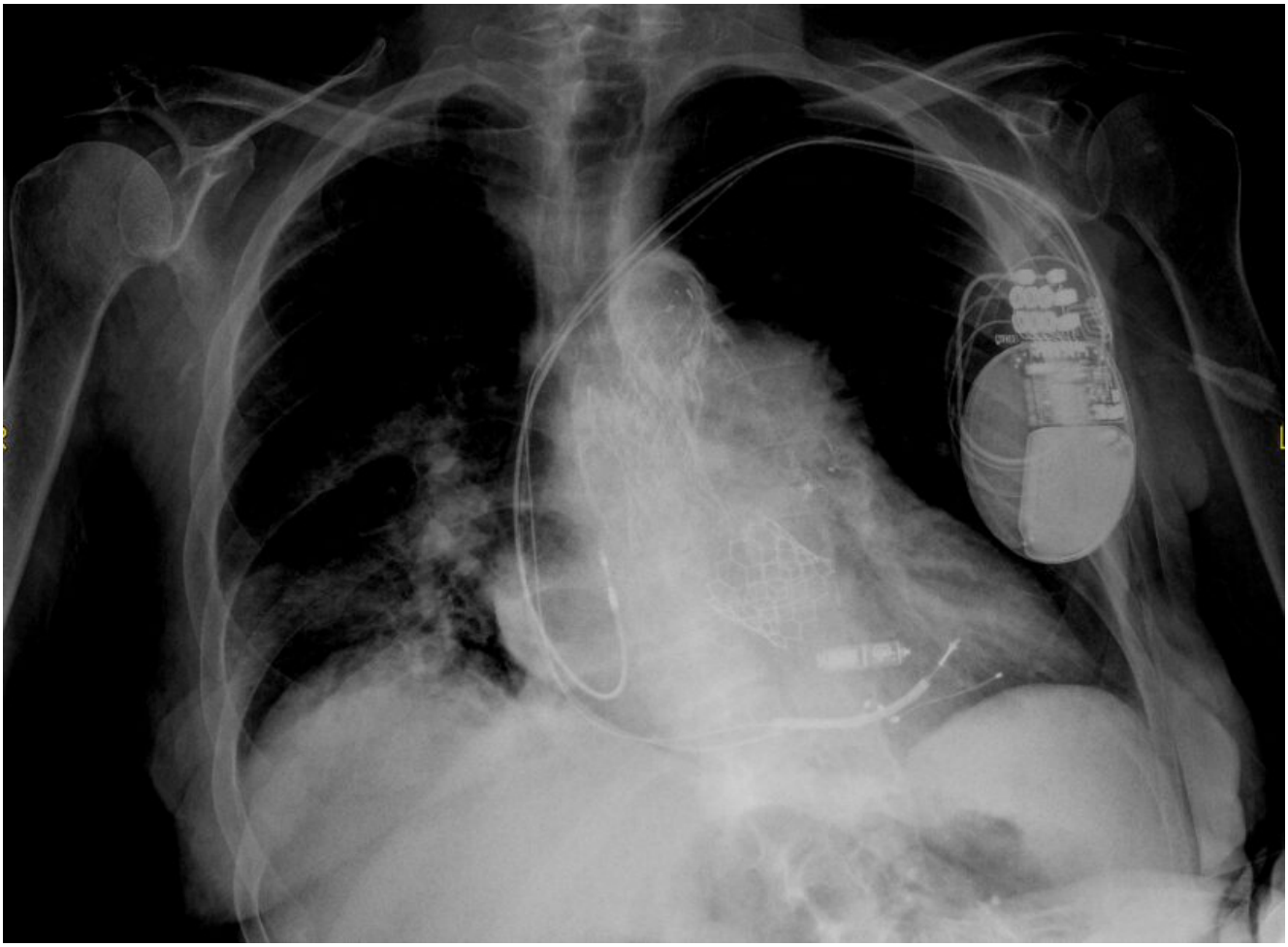

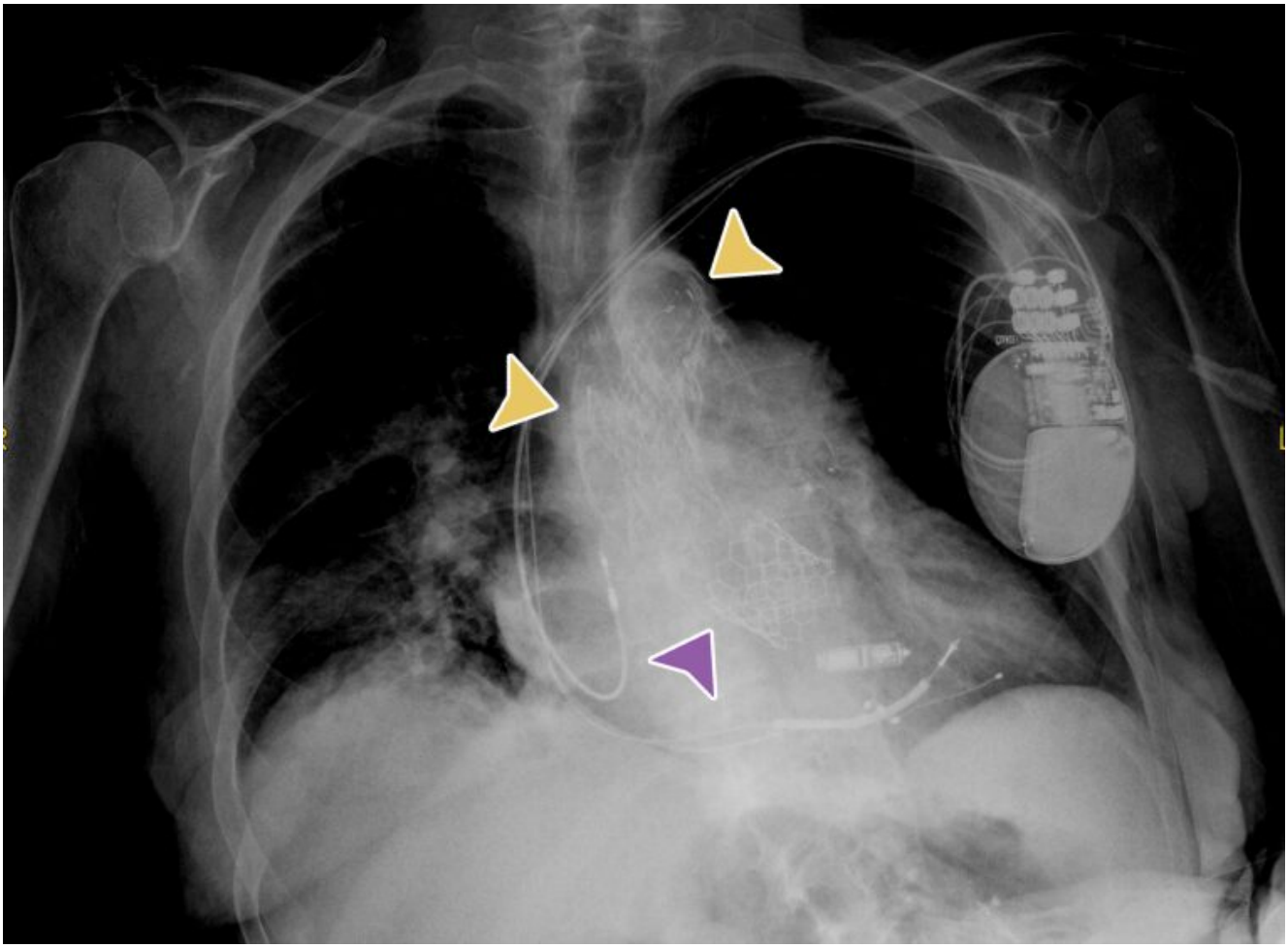

Practical Insights

- **Endovascular stent graphs in the ascending aorta are very rare.**
- **Valve-in-valve repairs of TAVRs are becoming more common.**
- **Know the complications of cardiac devices including migration.**
- **When in doubt, recommend a CT.**

Takeaway: One appropriately-positioned device doesn’t exclude other devices being malpositioned.

*Shared to improve patient safety and healthcare delivery in the provision of radiology services. The circumstances and facts are changed, altered, or deidentified to preserve confidentiality. Privileges have not been waived.*The Cardiothoracic Imaging Radiology National Subspecialty Division (NSD) is part of RP’s Clinical Value Team, which works to elevate patient care and enhance value through innovation, collaboration and education. To advance this goal, our radiologists and advanced practice providers are committed to sharing peer learning as valuable reminders and insights about what we encounter in our day-to-day practice. Check back here and on X, LinkedIn and Instagram to see these common cases and our findings.

Visit the Clinical Resources page for more cases and to see what we’ve developed to enhance best practice recommendations, elevate image quality and patient care and update current

standards throughout RP's network of practices, all to deliver excellent radiology services to patients, referring clinicians and client partners.



Radiology Partners, Inc., through RP Clinical Services and our managed practices, together with Mosaic Clinical Technologies, Inc., its technology and artificial intelligence division, is the leading global provider of radiology services, as well as related advanced technology and AI. Our network of 4,500-plus radiologists, based in over 40 countries, interprets more than 57 million imaging studies each year for 3,700 hospitals and other healthcare facilities in six countries. Learn more at radpartners.com and connect with us on LinkedIn, X, Instagram and YouTube.

Rad to Rad Learning: PE Diagnostic Quality vs. Accuracy

The Radiology Partners (RP)

Cardiothoracic Imaging National Subspecialty Division (NSD) presents our newest Rad to Rad Learning case.

Peer Learning Opportunity

Our ability to perceive a PE is governed by the enhancement level throughout the pulmonary arterial tree and how motion-free images are.

Adequate contrast enhancement is crucial to detect PE. These images are from the same patient. The left is 280HU and the right is 480HU.

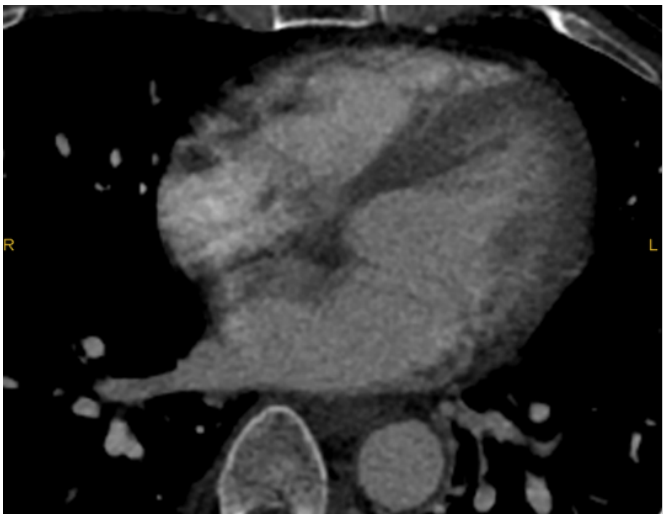

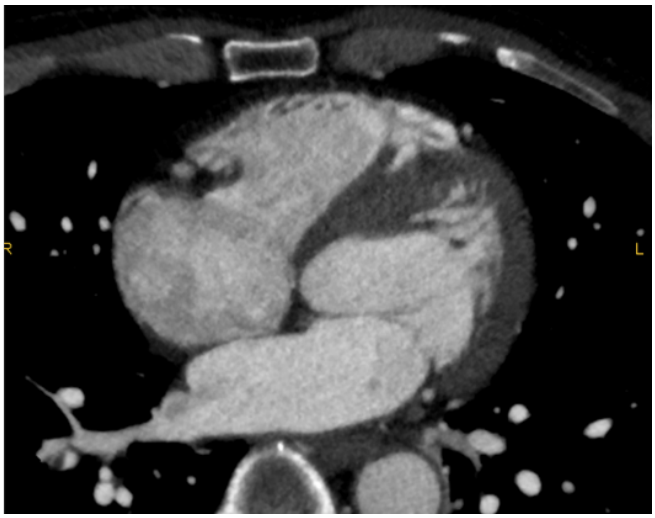

STAT CTA for Chest Pain to rule out PE:

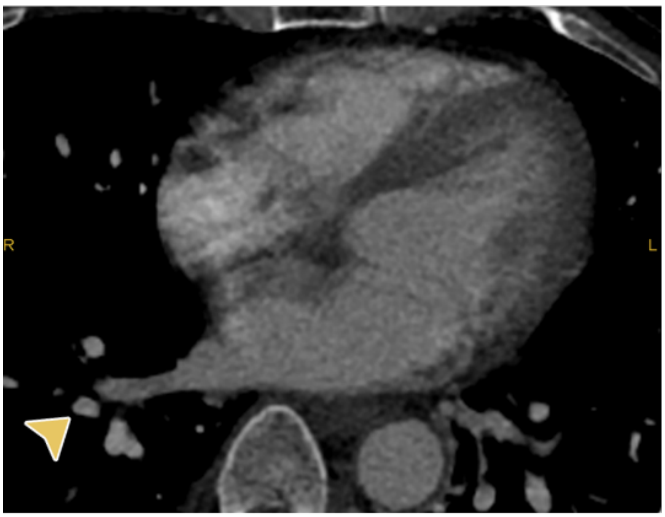

80 cc Omnipaque 350
@ 2.5 cc/sec

STAT Coronary CTA for Chest pain
5 minutes later:

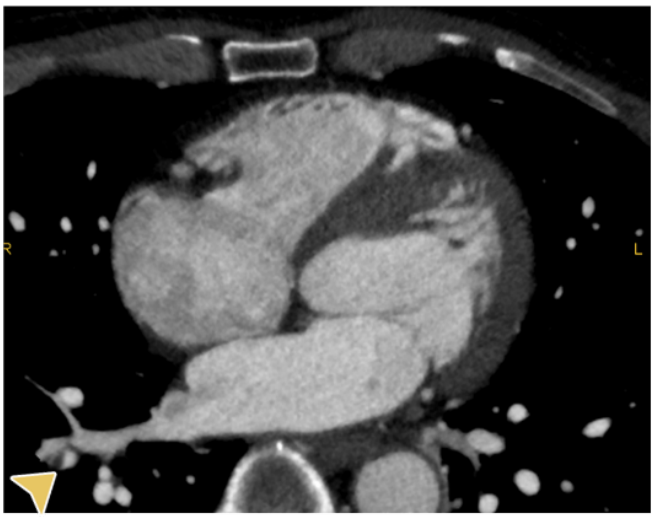

80 cc Omnipaque 350
@ 5 cc/sec

Practical Insights

- **Inadequate enhancement, especially below 250HU, can degrade visualization of distal emboli**
- **Visualization can be degraded in cases of significant motion, even if HU levels are adequate.**

Takeaway: “I don’t see a PE.” is not the same as “The enhancement is good enough for me to exclude a PE down to this pulmonary arterial division.”

Shared to improve patient safety and healthcare delivery in the provision of radiology services. The circumstances and

*facts are changed, altered, or deidentified to preserve confidentiality. Privileges have not been waived.*The Cardiothoracic Imaging Radiology National Subspecialty Division (NSD) is part of RP's Clinical Value Team, which works to elevate patient care and enhance value through innovation, collaboration and education. To advance this goal, our radiologists and advanced practice providers are committed to sharing peer learning as valuable reminders and insights about what we encounter in our day-to-day practice. Check back here and on X, LinkedIn and Instagram to see these common cases and our findings.

Visit the Clinical Resources page for more cases and to see what we've developed to enhance best practice recommendations, elevate image quality and patient care and update current standards throughout RP's network of practices, all to deliver excellent radiology services to patients, referring clinicians and client partners.



Radiology Partners, through RP Clinical Services and its managed practices, together with Mosaic Clinical Technologies, Inc., its technology and AI division, is the leading provider of technology-enabled radiology services in the U.S., serving more than 3,400 hospitals and other healthcare facilities with high-quality radiology, technology and artificial intelligence solutions. As a physician-led and physician-owned practice, our mission is to transform radiology by innovating across clinical value, technology, and service, while elevating the role of radiology and radiologists in healthcare. For the

latest news from RP, follow us on X, LinkedIn, Instagram, YouTube and the blog.

Rad to Rad Learning: Olecranon Bursitis

The Radiology Partners (RP) MSK National Subspecialty Division (NSD) presents our newest Rad to Rad Learning case.

Peer Learning Opportunity

Is this soft tissue swelling?

Septic bursitis is less common but often requires immediate medical attention.





1/3 of all olecranon bursitis cases are septic.

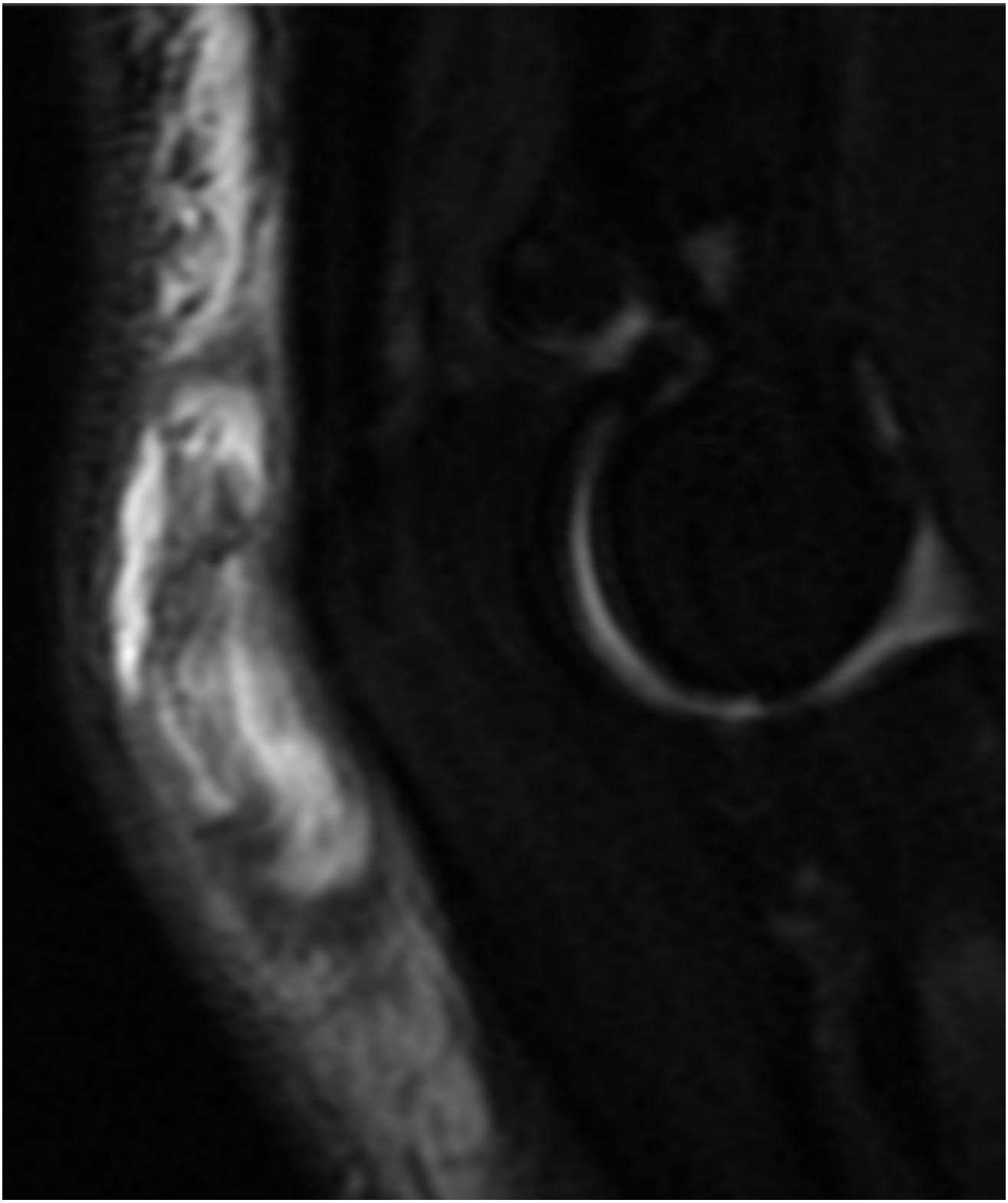

Practical Insights

- Sequalae of untreated septic bursitis, if untreated, can lead to pyomyositis, septic

arthritis, or osteomyelitis.

- **Include in differential for soft tissue swelling over olecranon.**
- **Inflammatory conditions associated with olecranon bursitis (CPPD, gout, RA).**
- **Trauma (prone to injury with superficial location).**

Takeaway: One of the few MSK soft tissue diagnoses identified by x-ray.

*Shared to improve patient safety and healthcare delivery in the provision of radiology services. The circumstances and facts are changed, altered, or deidentified to preserve confidentiality. Privileges have not been waived.*The MSK Radiology National Subspecialty Division (NSD) is part of RP's Clinical Value Team, which works to elevate patient care and enhance value through innovation, collaboration and education. To advance this goal, our radiologists and advanced practice providers are committed to sharing peer learning as valuable reminders and insights about what we encounter in our day-to-day practice. Check back here and on X, LinkedIn and Instagram to see these common cases and our findings.

Visit the Clinical Resources page for more cases and to see what we've developed to enhance best practice recommendations, elevate image quality and patient care and update current standards throughout RP's network of practices, all to deliver excellent radiology services to patients, referring clinicians and client partners.



Radiology Partners, through RP Clinical Services and its managed practices, together with Mosaic Clinical Technologies, Inc., its technology and AI division, is the leading provider of technology-enabled radiology services in the U.S., serving more than 3,400 hospitals and other healthcare facilities with high-quality radiology, technology and artificial intelligence solutions. As a physician-led and physician-owned practice, our mission is to transform radiology by innovating across clinical value, technology, and service, while elevating the role of radiology and radiologists in healthcare. For the latest news from RP, follow us on X, LinkedIn, Instagram, YouTube and the blog.

Rad to Rad Learning: Non-Mass Lesions on US

The Radiology Partners (RP) Breast Imaging National Subspecialty Division (NSD) presents our newest

Rad to Rad Learning case.

Peer Learning Opportunity

These are images of a patient with heterogeneously dense breasts who was recommended for a supplemental screening breast US.

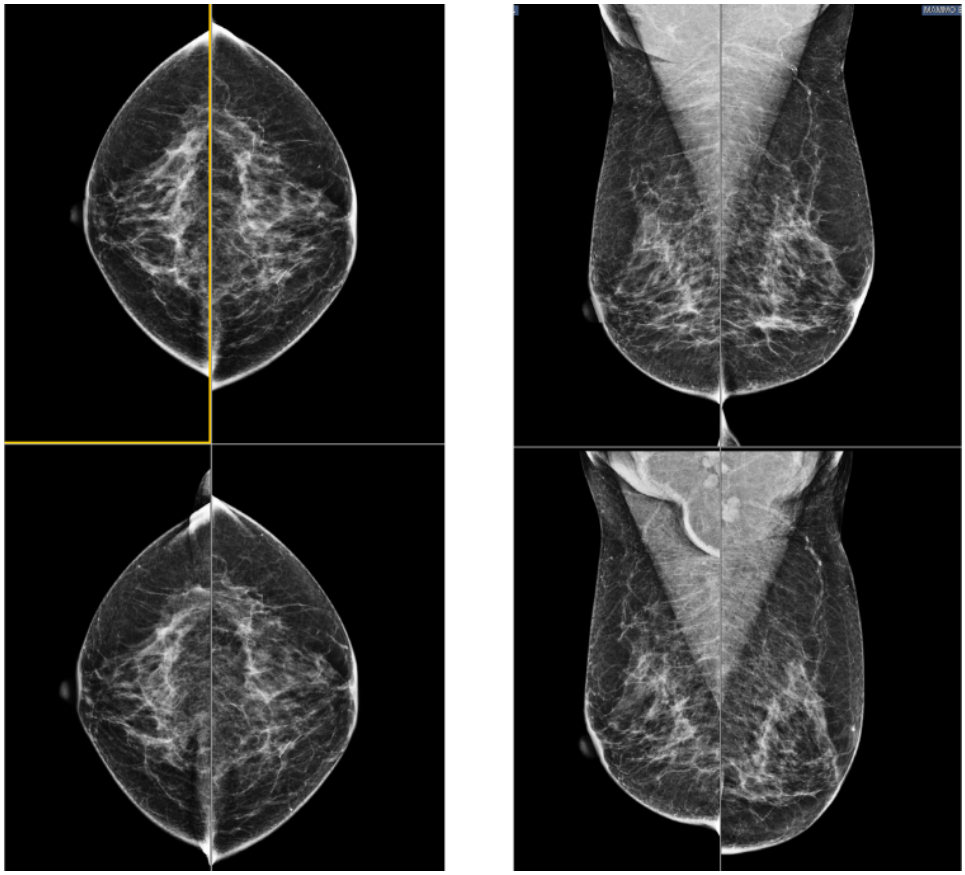

The patient was found to have a new “non-mass” lesion in the right 2:00 axis which was recommended for biopsy. It was DCIS,

stage 0 breast cancer. It appeared as a serpiginous, hypoechoic structure.

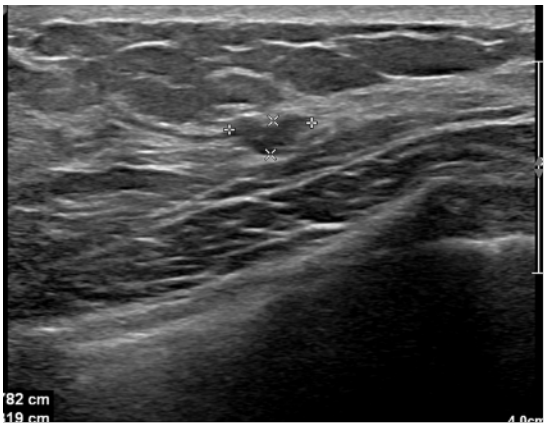

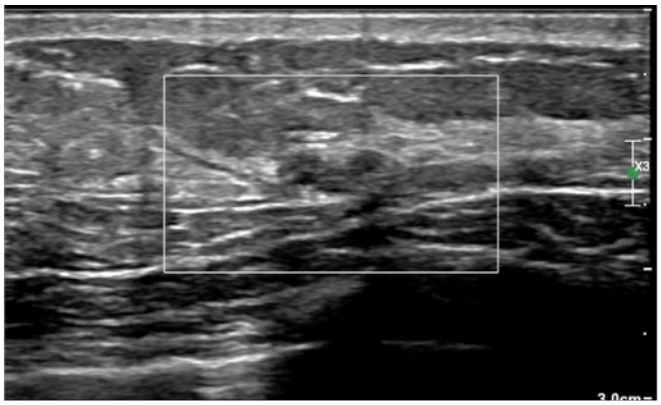

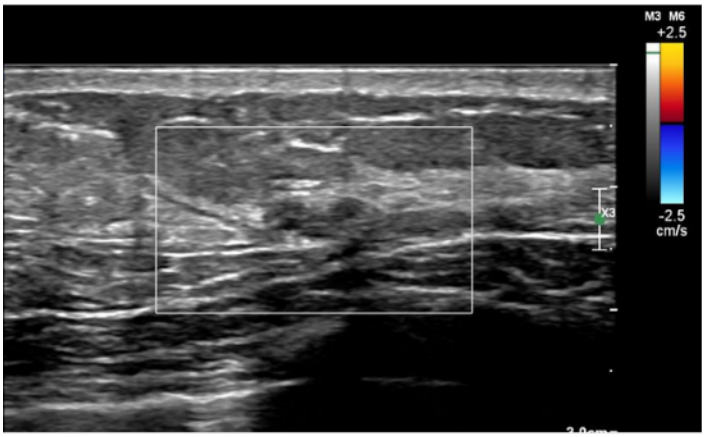

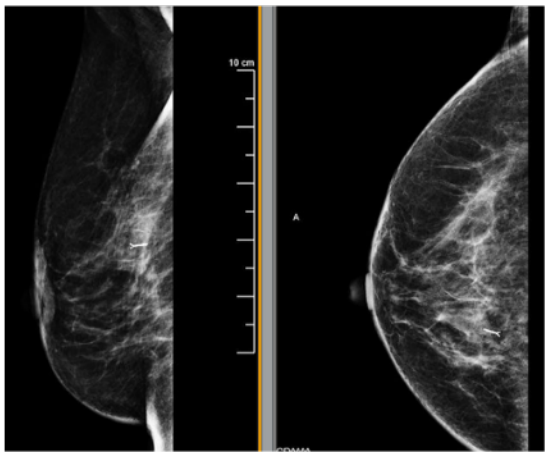

Practical Insights

- New terminology added to 2025 BI-RADS.
- Can be identified as distinctly different from normal tissue, seen in 3 dimensions but lacks the discrete margination of a mass and cannot be assigned a specific shape.
- Often subtle and may be detected only because the background tissue is disrupted. If it is a new or isolated finding, it may be considered suspicious.

Takeaway: New ultrasound descriptor that could correlate with benign and malignant findings.

*Shared to improve patient safety and healthcare delivery in the provision of radiology services. The circumstances and facts are changed, altered, or deidentified to preserve confidentiality. Privileges have not been waived.*The Breast Imaging National Subspecialty Division (NSD) is part of RP's Clinical Value Team, which works to elevate patient care and enhance value through innovation, collaboration and education. To advance this goal, our radiologists and advanced practice providers are committed to sharing peer learning as valuable reminders and insights about what we encounter in our day-to-day practice. Check back here and on X, LinkedIn and Instagram to see these common cases and our findings.

Visit the Clinical Resources page for more cases and to see what we've developed to enhance best practice recommendations, elevate image quality and patient care and update current standards throughout RP's network of practices, all to deliver excellent radiology services to patients, referring clinicians and client partners.



Radiology Partners, through RP Clinical Services and its managed practices, together with Mosaic Clinical Technologies, Inc., its technology and AI division, is the leading provider of technology-enabled radiology services in the U.S., serving

more than 3,400 hospitals and other healthcare facilities with high-quality radiology, technology and artificial intelligence solutions. As a physician-led and physician-owned practice, our mission is to transform radiology by innovating across clinical value, technology, and service, while elevating the role of radiology and radiologists in healthcare. For the latest news from RP, follow us on X, LinkedIn, Instagram, YouTube and the blog.

Rad to Rad Learning: Imaging Technique Matters

The Radiology Partners (RP) Breast Imaging National Subspecialty Division (NSD) presents our newest Rad to Rad Learning case.



Peer Learning Opportunity

Something is missing from this right CC view.

In the original scan, the image was

exaggerated laterally, which resulted in excluded medial tissue.

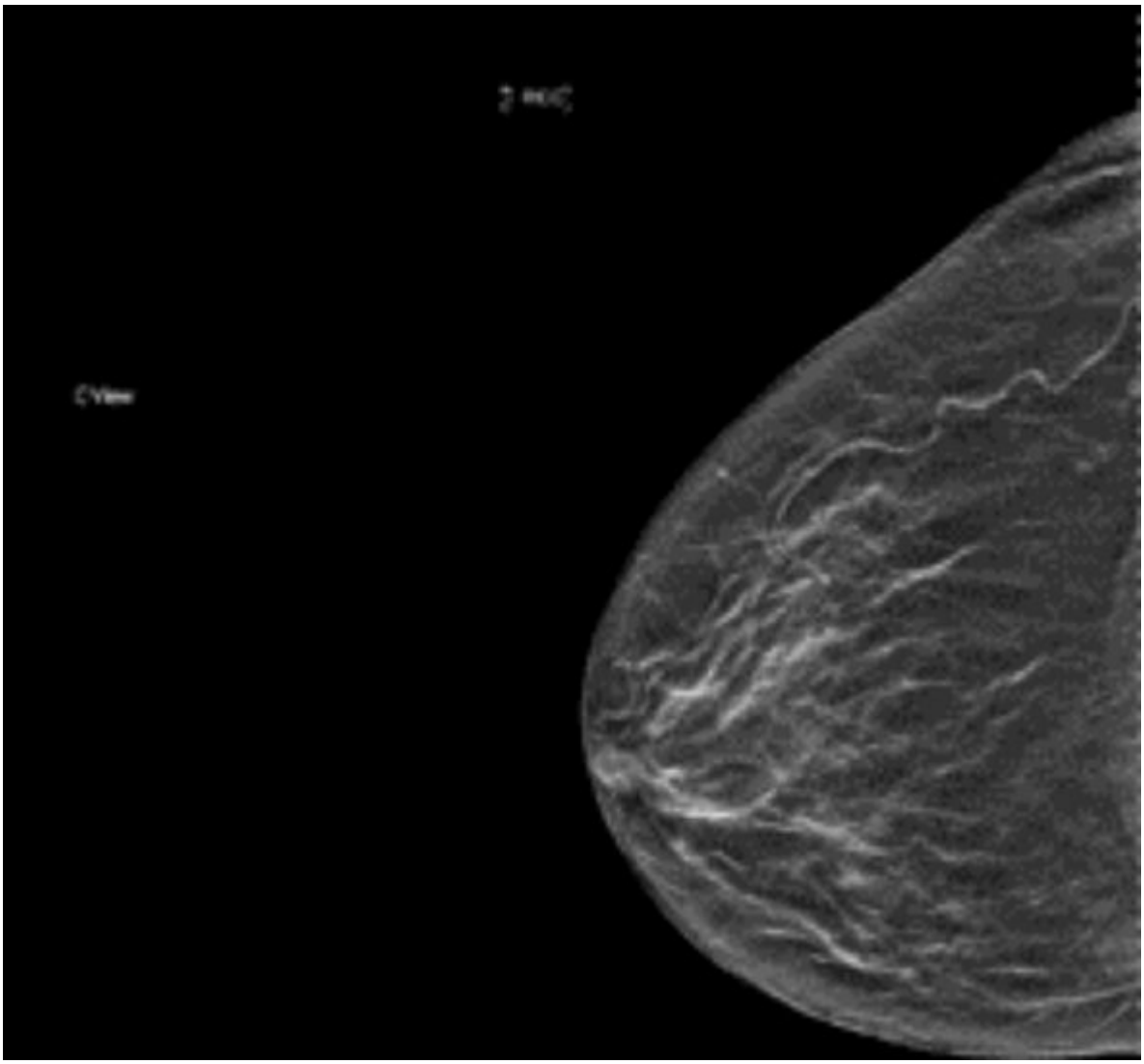

A second scan was performed with proper technique, and a mass that was previously out of frame became visible.

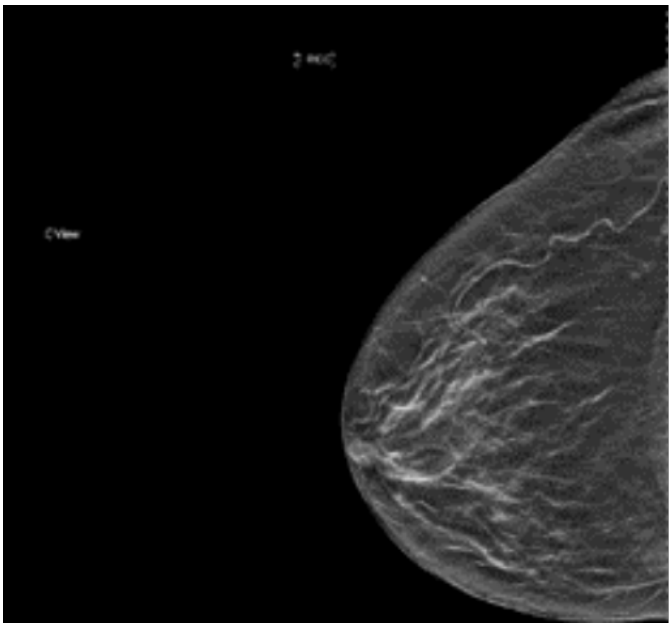

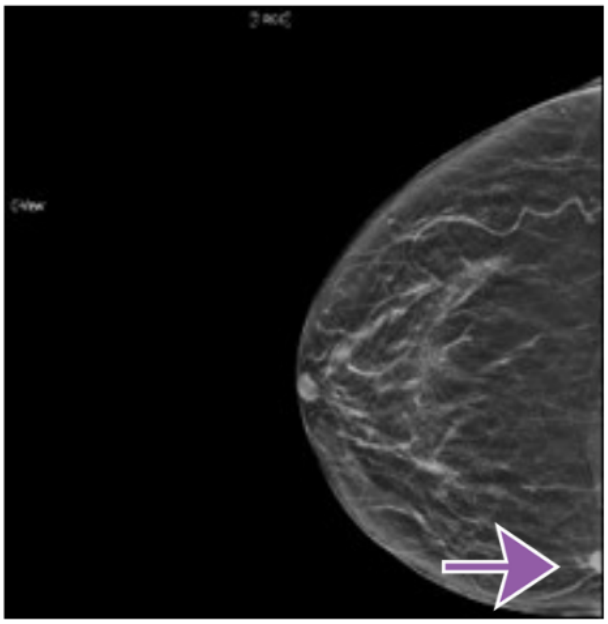

Practical Insights

- **Do not accept suboptimal patient positioning.**
- **For CC, the posterior nipple line should bisect the breast into equal halves, with only fat or muscle in the retroglandular space.**
- **For MLO, the pectoralis muscle should extend to the posterior nipple line with a convex anterior margin of the pectoralis muscle. The inframammary fold should be open.**

Takeaway: You can’t find cancers you can’t see.

*Shared to improve patient safety and healthcare delivery in the provision of radiology services. The circumstances and facts are changed, altered, or deidentified to preserve confidentiality. Privileges have not been waived.*The Breast

Imaging National Subspecialty Division (NSD) is part of RP's Clinical Value Team, which works to elevate patient care and enhance value through innovation, collaboration and education. To advance this goal, our radiologists and advanced practice providers are committed to sharing peer learning as valuable reminders and insights about what we encounter in our day-to-day practice. Check back here and on X, LinkedIn and Instagram to see these common cases and our findings.

Visit the Clinical Resources page for more cases and to see what we've developed to enhance best practice recommendations, elevate image quality and patient care and update current standards throughout RP's network of practices, all to deliver excellent radiology services to patients, referring clinicians and client partners.



Radiology Partners, through RP Clinical Services and its managed practices, together with Mosaic Clinical Technologies, Inc., its technology and AI division, is the leading provider of technology-enabled radiology services in the U.S., serving more than 3,400 hospitals and other healthcare facilities with high-quality radiology, technology and artificial intelligence solutions. As a physician-led and physician-owned practice, our mission is to transform radiology by innovating across clinical value, technology, and service, while elevating the role of radiology and radiologists in healthcare. For the latest news from RP, follow us on X, LinkedIn, Instagram, YouTube and the blog.

Rad to Rad Learning: Masses Obscured by Implants

The Radiology Partners (RP) Breast Imaging National Subspecialty Division (NSD) presents our newest Rad to Rad Learning case.



Peer Learning Opportunity

How much time do you spend looking at implant-included views?

Proper technique is important for implant-included views. While they can be more difficult, they can also provide more information.

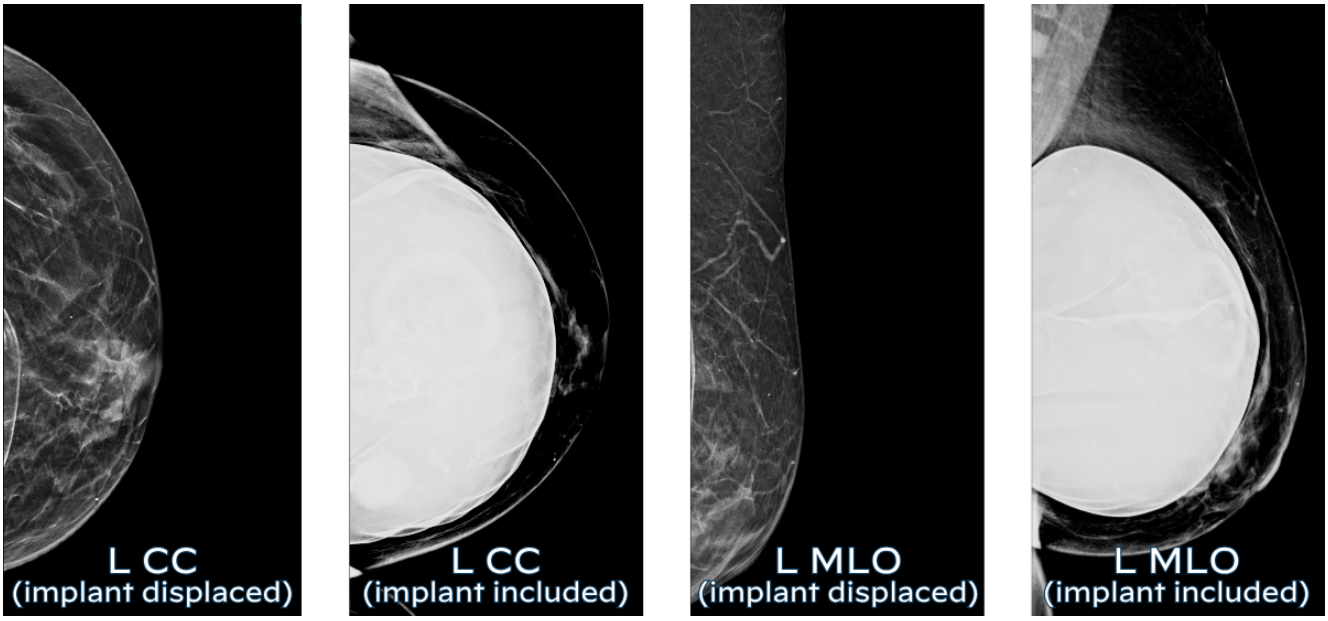

W/L adjustment on the implant-included L CC view shows an irregular mass seen through the radiolucent saline implant. 2) US of mass. 3) MR of mass.

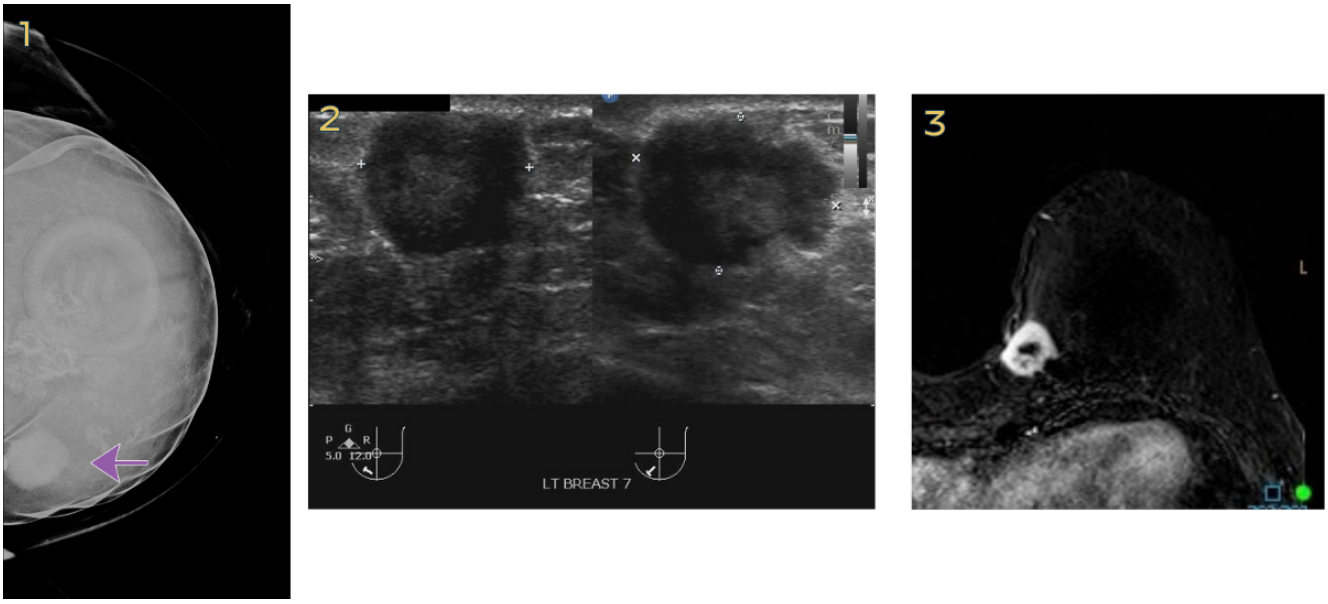

Practical Insights

- **Implants obscure breast tissue.**

- **Standard implant imaging includes both implant-included and implant displaced (Eklund) views.**
- **Implant displaced (ID) views exclude posterior tissues.**
- **Saline implants are radiolucent.**

Takeaway: Implant views are critical!

*Shared to improve patient safety and healthcare delivery in the provision of radiology services. The circumstances and facts are changed, altered, or deidentified to preserve confidentiality. Privileges have not been waived.*The Breast Imaging National Subspecialty Division (NSD) is part of RP's Clinical Value Team, which works to elevate patient care and enhance value through innovation, collaboration and education. To advance this goal, our radiologists and advanced practice providers are committed to sharing peer learning as valuable reminders and insights about what we encounter in our day-to-day practice. Check back here and on X, LinkedIn and Instagram to see these common cases and our findings.

Visit the Clinical Resources page for more cases and to see what we've developed to enhance best practice recommendations, elevate image quality and patient care and update current standards throughout RP's network of practices, all to deliver excellent radiology services to patients, referring clinicians and client partners.

Radiology Partners, through RP Clinical Services and its managed practices, together with Mosaic Clinical Technologies, Inc., its technology and AI division, is the leading provider of technology-enabled radiology services in the U.S., serving more than 3,400 hospitals and other healthcare facilities with high-quality radiology, technology and artificial intelligence solutions. As a physician-led and physician-owned practice, our mission is to transform radiology by innovating across clinical value, technology, and service, while elevating the role of radiology and radiologists in healthcare. For the latest news from RP, follow us on X, LinkedIn, Instagram, YouTube and the blog.

Rad to Rad Learning: Missed Breast Cancer on Chest CT

The Radiology Partners (RP) Breast Imaging National Subspecialty Division (NSD) presents our newest

Rad to Rad Learning case.

Peer Learning Opportunity

A 70 y/o female presented to the ER with palpitations and received a chest CT. She was ultimately diagnosed with atrial fibrillation. What did the radiologist miss?

In this case, the radiologist missed an invasive mammary carcinoma! Incidental breast cancers on chest CTs are missed 64% of the time.

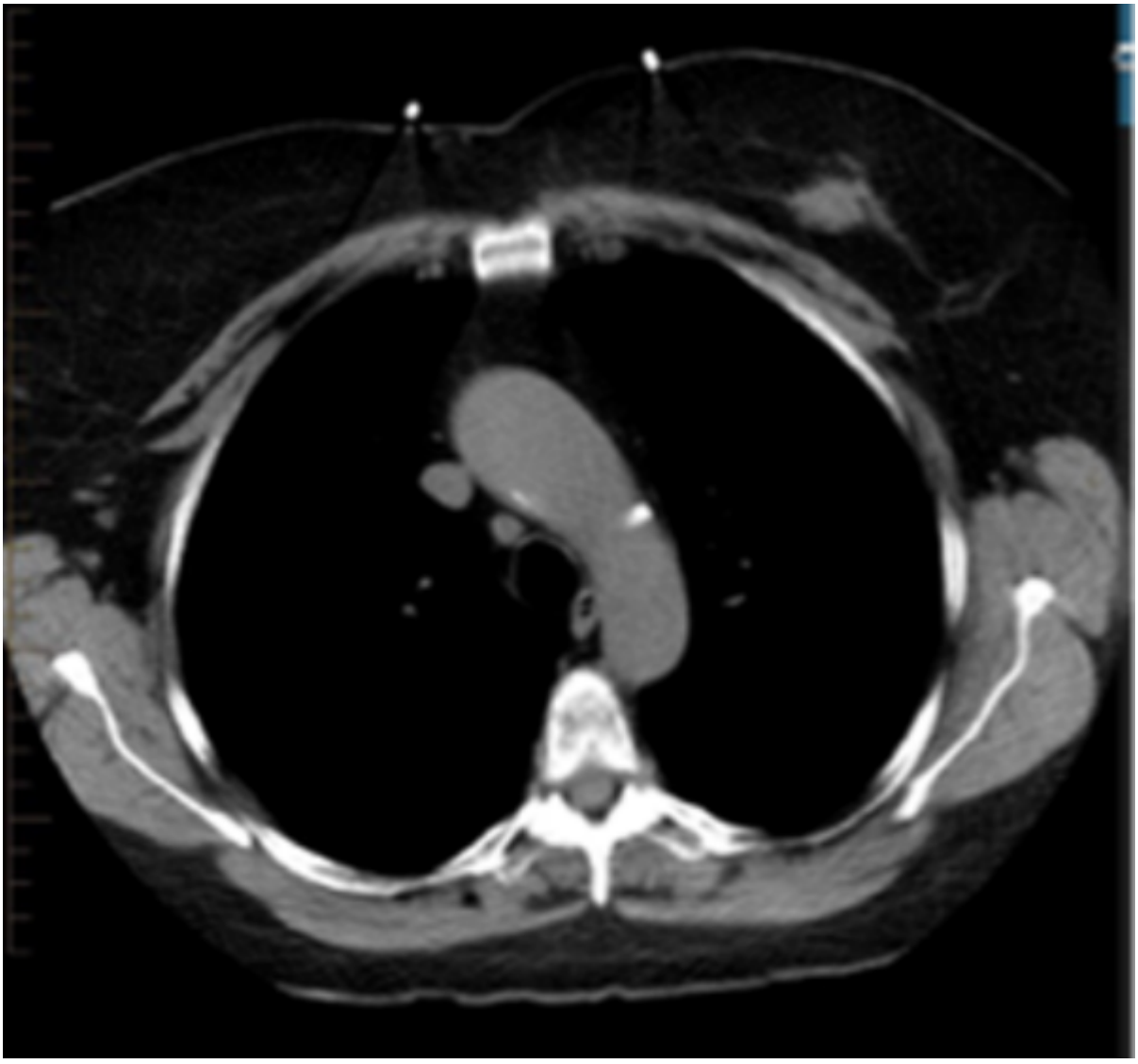

Remember to review breast tissue in your search pattern.

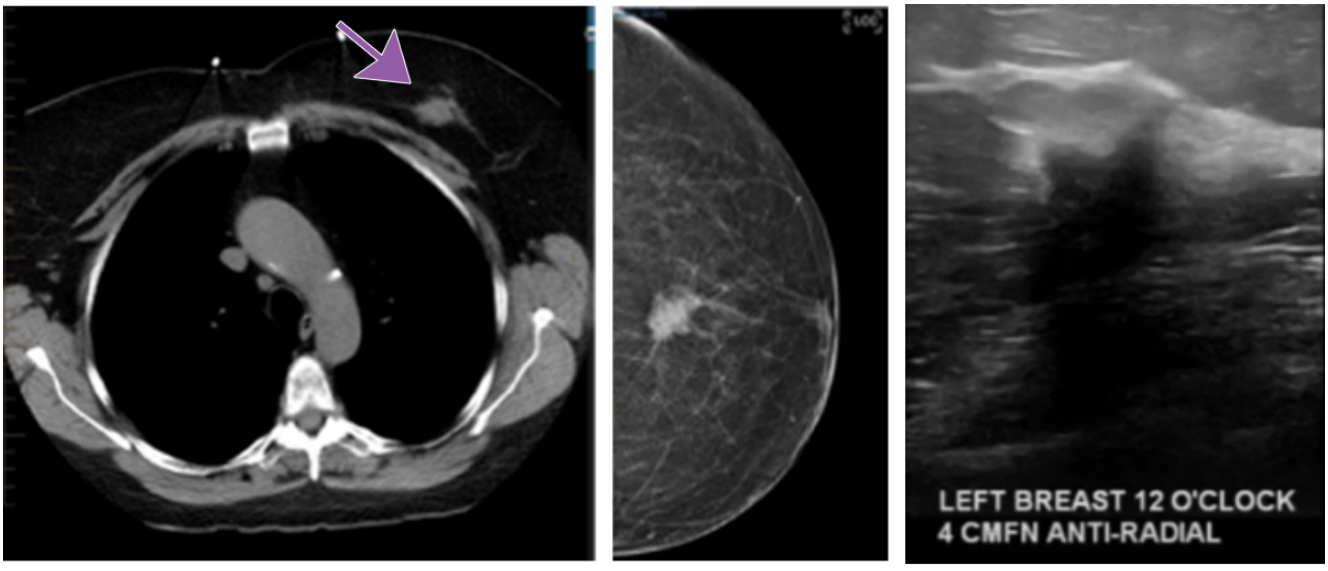

Practical Insights

- **During a Chest CT the primary focus is on evaluating other anatomy, and breast tissue is easy to overlook.**
- **Not all eligible women undergo mammographic screening, and incidental findings on unrelated chest CTs are the only way their cancer is found.**
- **Remember to review breast tissue in FOV.**
- **Early detection saves lives.**

Takeaway: Chest CTs include breasts!

*Shared to improve patient safety and healthcare delivery in the provision of radiology services. The circumstances and facts are changed, altered, or deidentified to preserve confidentiality. Privileges have not been waived.*The Breast Imaging National Subspecialty Division (NSD) is part of RP's Clinical Value Team, which works to elevate patient care and enhance value through innovation, collaboration and education. To advance this goal, our radiologists and advanced practice providers are committed to sharing peer learning as valuable reminders and insights about what we encounter in our day-to-day practice. Check back here and on X, LinkedIn and Instagram to see these common cases and our findings.

Visit the Clinical Resources page for more cases and to see what we've developed to enhance best practice recommendations, elevate image quality and patient care and update current standards throughout RP's network of practices, all to deliver excellent radiology services to patients, referring clinicians

and client partners.



Radiology Partners, through RP Clinical Services and its managed practices, together with Mosaic Clinical Technologies, Inc., its technology and AI division, is the leading provider of technology-enabled radiology services in the U.S., serving more than 3,400 hospitals and other healthcare facilities with high-quality radiology, technology and artificial intelligence solutions. As a physician-led and physician-owned practice, our mission is to transform radiology by innovating across clinical value, technology, and service, while elevating the role of radiology and radiologists in healthcare. For the latest news from RP, follow us on X, LinkedIn, Instagram, YouTube and the blog.

Rad to Rad Learning: Epidural Hematoma

The Radiology Partners (RP) Neuroradiology National

Subspecialty Division (NSD) presents our newest Rad to Rad Learning case.



Peer Learning Opportunity

Rapid expansion is common reaching maximum size at 36 hours resulting in neurologic deficits and death in up to 5% due to herniations.

Hyperdense biconvex unilateral extra axial collection adjacent to a skull fracture in 75% of cases.

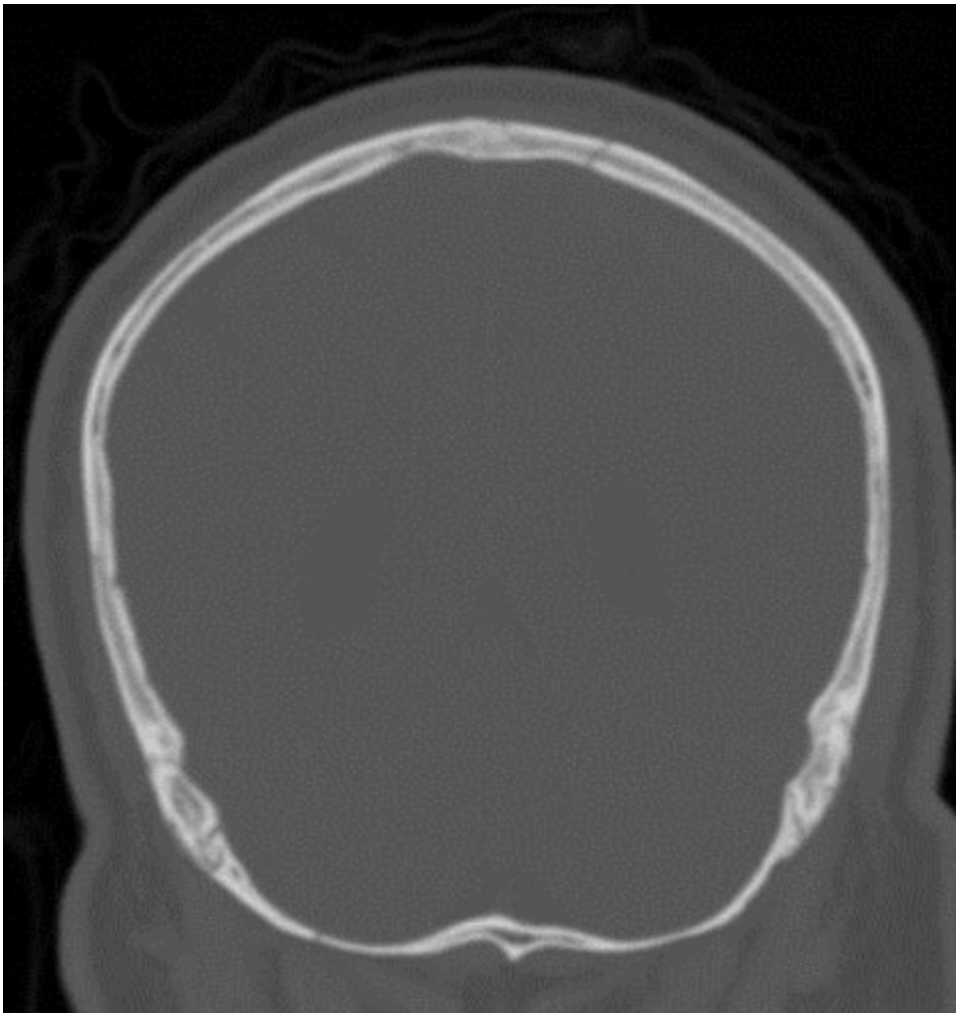



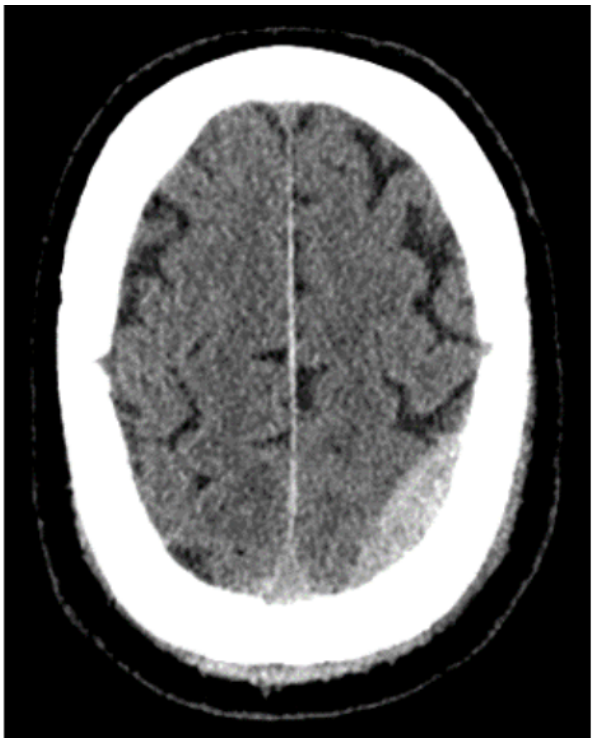

Practical Insights

- **Common “lucid interval” in up to 50% of cases.**
- **Typically associated with arterial laceration, but up to 10% are venous.**
- **Consider CTV if collection crosses suture.**
- **Bilateral EDH have up to 15-20% mortality rate.**

Takeaway: Use bone window to look for fracture.

*Shared to improve patient safety and healthcare delivery in the provision of radiology services. The circumstances and facts are changed, altered, or deidentified to preserve confidentiality. Privileges have not been waived.*The Neuroradiology National Subspecialty Division (NSD) is part of RP’s Clinical Value Team, which works to elevate patient care and enhance value through innovation, collaboration and education. To advance this goal, our radiologists and advanced practice providers are committed to sharing peer learning as valuable reminders and insights about what we encounter in our day-to-day practice. Check back here and on X, LinkedIn and Instagram to see these common cases and our findings.

Visit the Clinical Resources page for more cases and to see what we’ve developed to enhance best practice recommendations, elevate image quality and patient care and update current standards throughout RP’s network of practices, all to deliver excellent radiology services to patients, referring clinicians and client partners.

Radiology Partners, through RP Clinical Services and its managed practices, together with Mosaic Clinical Technologies, Inc., its technology and AI division, is the leading provider of technology-enabled radiology services in the U.S., serving more than 3,400 hospitals and other healthcare facilities with high-quality radiology, technology and artificial intelligence solutions. As a physician-led and physician-owned practice, our mission is to transform radiology by innovating across clinical value, technology, and service, while elevating the role of radiology and radiologists in healthcare. For the latest news from RP, follow us on X, LinkedIn, Instagram, YouTube and the blog.

Rad to Rad Learning: Cerebral Amyloid Angiopathy

The Radiology Partners (RP) Neuroradiology National Subspecialty Division

(NSD) presents our newest Rad to Rad Learning case.

Peer Learning Opportunity

Early imaging-based diagnosis is critical, as hemorrhagic complications can be mitigated by avoiding certain therapies.

Superficial siderosis, sequalae of bilateral microhemorrhages and large parenchymal hemorrhage.

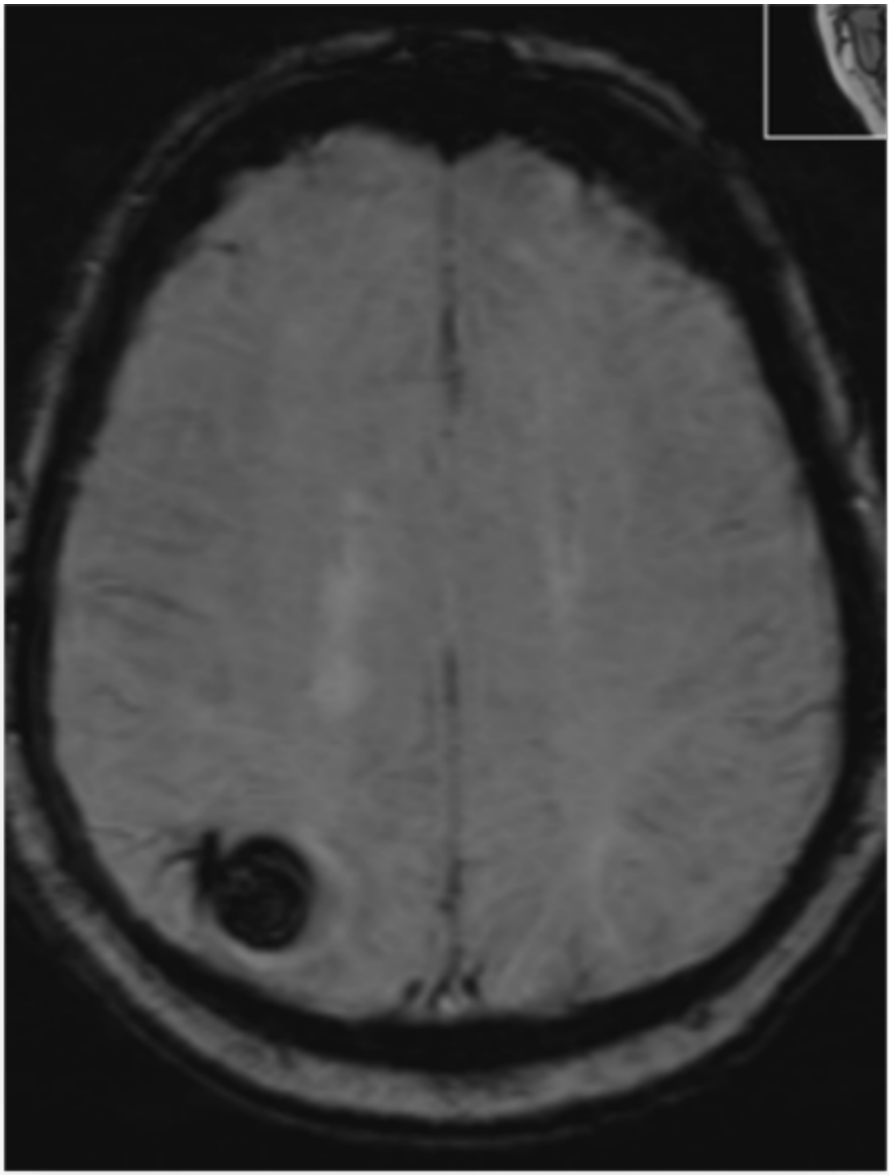

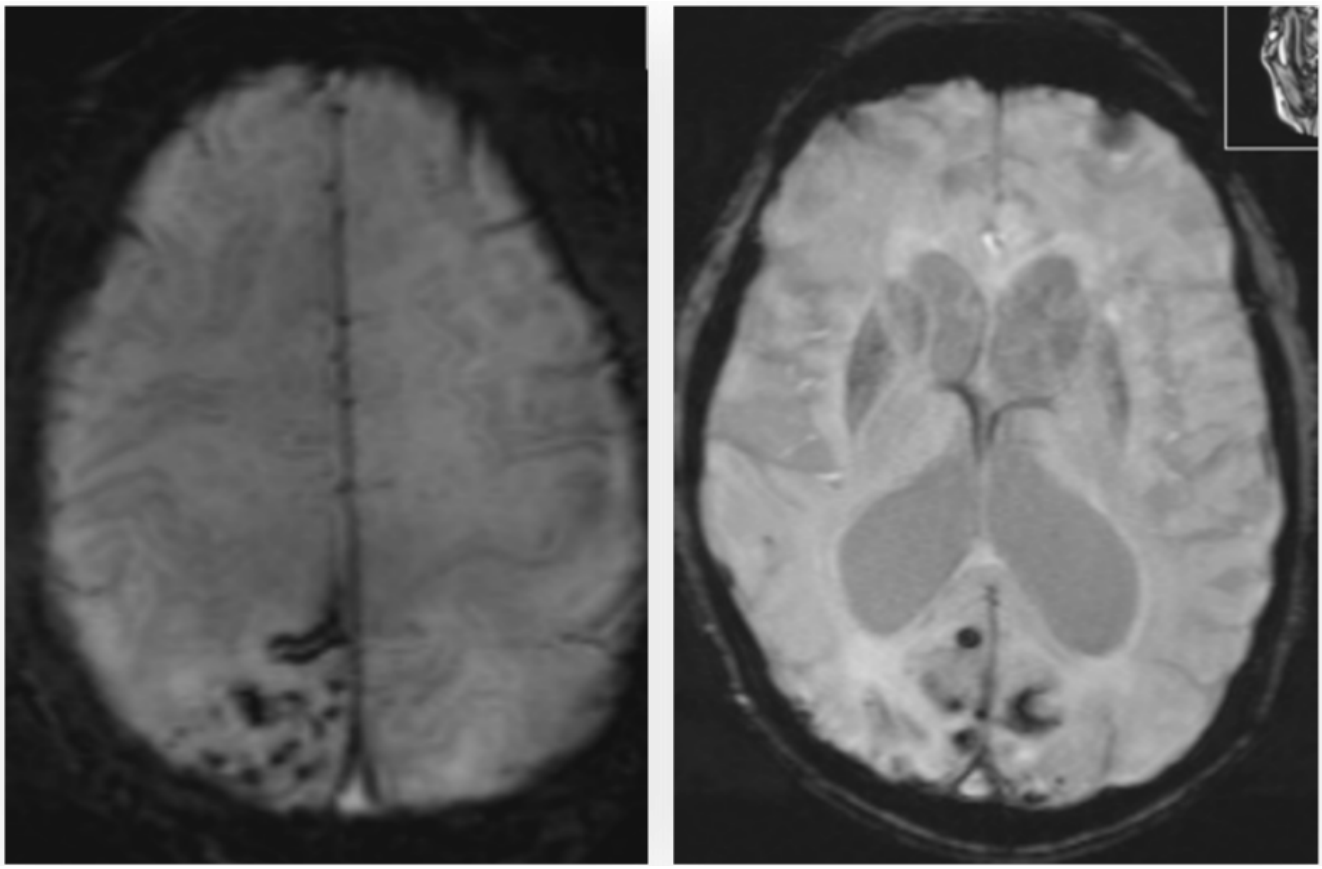

Practical Insights

- Causes up to 1/5 of primary intracranial hemorrhage in patients >60 years.
- Boston criteria are used for diagnosis without biopsy using presence of multiple asymmetric lobar microhemorrhages, cortical superficial siderosis, and lobar ICH.
- Other markers are multiple dilated perivascular spaces and white matter T2 hyperintensities (70%).
- May show sulcal or leptomeningeal enhancement or focal nonhemorrhagic mass (amyloidoma) extending to the ventricular wall in younger patients.

Takeaway: Suspect CAA in normotensive patients with multiple types of non-traumatic hemorrhages.

*Shared to improve patient safety and healthcare delivery in the provision of radiology services. The circumstances and facts are changed, altered, or deidentified to preserve confidentiality. Privileges have not been waived.*The Neuroradiology National Subspecialty Division (NSD) is part of RP's Clinical Value Team, which works to elevate patient care and enhance value through innovation, collaboration and education. To advance this goal, our radiologists and advanced practice providers are committed to sharing peer learning as valuable reminders and insights about what we encounter in our day-to-day practice. Check back here and on X, LinkedIn and Instagram to see these common cases and our findings.

Visit the Clinical Resources page for more cases and to see what we've developed to enhance best practice recommendations, elevate image quality and patient care and update current standards throughout RP's network of practices, all to deliver excellent radiology services to patients, referring clinicians and client partners.



Radiology Partners, through RP Clinical Services and its managed practices, together with Mosaic Clinical Technologies, Inc., its technology and AI division, is the leading provider

of technology-enabled radiology services in the U.S., serving more than 3,400 hospitals and other healthcare facilities with high-quality radiology, technology and artificial intelligence solutions. As a physician-led and physician-owned practice, our mission is to transform radiology by innovating across clinical value, technology, and service, while elevating the role of radiology and radiologists in healthcare. For the latest news from RP, follow us on X, LinkedIn, Instagram, YouTube and the blog.

Rad to Rad Learning: Osteomyelitis

The Radiology Partners (RP) MSK National Subspecialty Division (NSD) presents our newest Rad to Rad Learning case.



Peer Learning Opportunity

T1 marrow replacement is not necessary to diagnose osteomyelitis in the presence of subjacent ulcers.

T1 signal is darker than muscle (marrow replacement).

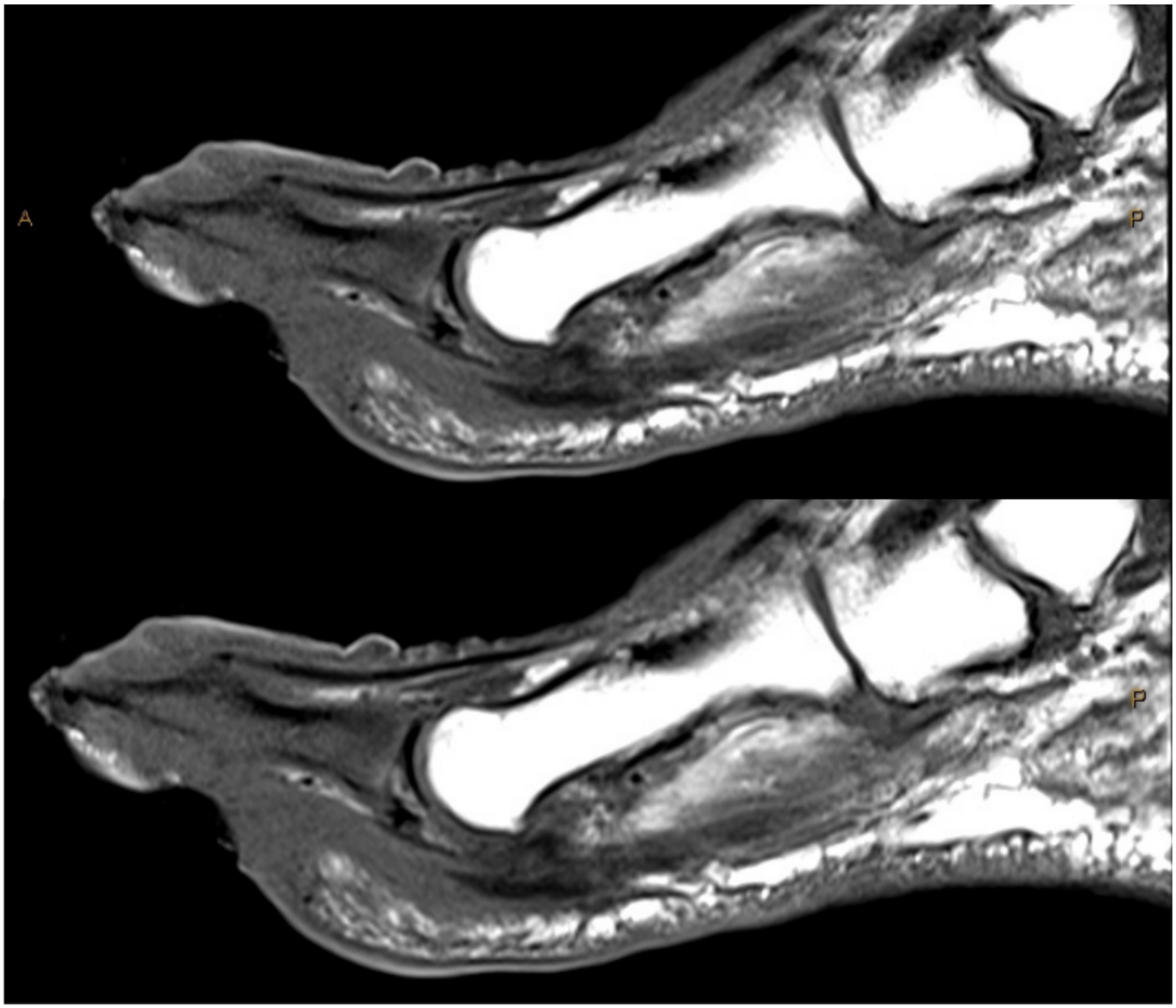

T2 edema signal.

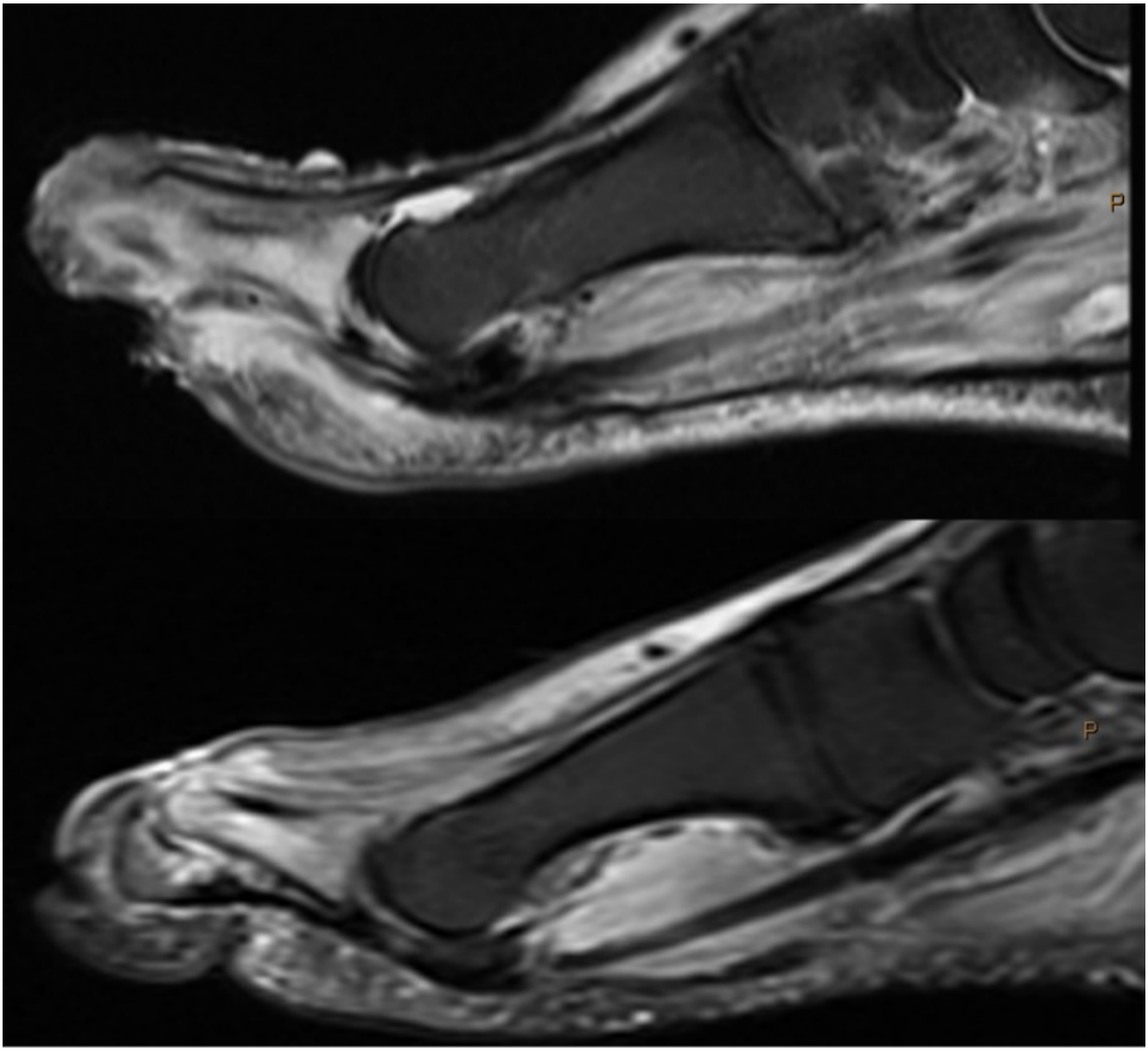

Practical Insights

- Bone marrow edema signal with T1 marrow replacement is consistent with osteomyelitis.
- Bone marrow edema signal without T1 marrow replacement with adjacent ulcer,

abscess, or sinus tract indicates “high likelihood of osteomyelitis”.

🔔 Takeaway: Osteo – likely no contrast needed.

*Shared to improve patient safety and healthcare delivery in the provision of radiology services. The circumstances and facts are changed, altered, or deidentified to preserve confidentiality. Privileges have not been waived.*The MSK National Subspecialty Division (NSD) is part of RP’s Clinical Value Team, which works to elevate patient care and enhance value through innovation, collaboration and education. To advance this goal, our radiologists and advanced practice providers are committed to sharing peer learning as valuable reminders and insights about what we encounter in our day-to-day practice. Check back here and on X, LinkedIn and Instagram to see these common cases and our findings.

Visit the Clinical Resources page for more cases and to see what we’ve developed to enhance best practice recommendations, elevate image quality and patient care and update current standards throughout RP’s network of practices, all to deliver excellent radiology services to patients, referring clinicians and client partners.



Radiology Partners, through RP Clinical Services and its managed practices, together with Mosaic Clinical Technologies, Inc., its technology and AI division, is the leading provider of technology-enabled radiology services in the U.S., serving more than 3,400 hospitals and other healthcare facilities with high-quality radiology, technology and artificial intelligence solutions. As a physician-led and physician-owned practice, our mission is to transform radiology by innovating across clinical value, technology, and service, while elevating the role of radiology and radiologists in healthcare. For the latest news from RP, follow us on X, LinkedIn, Instagram, YouTube and the blog.