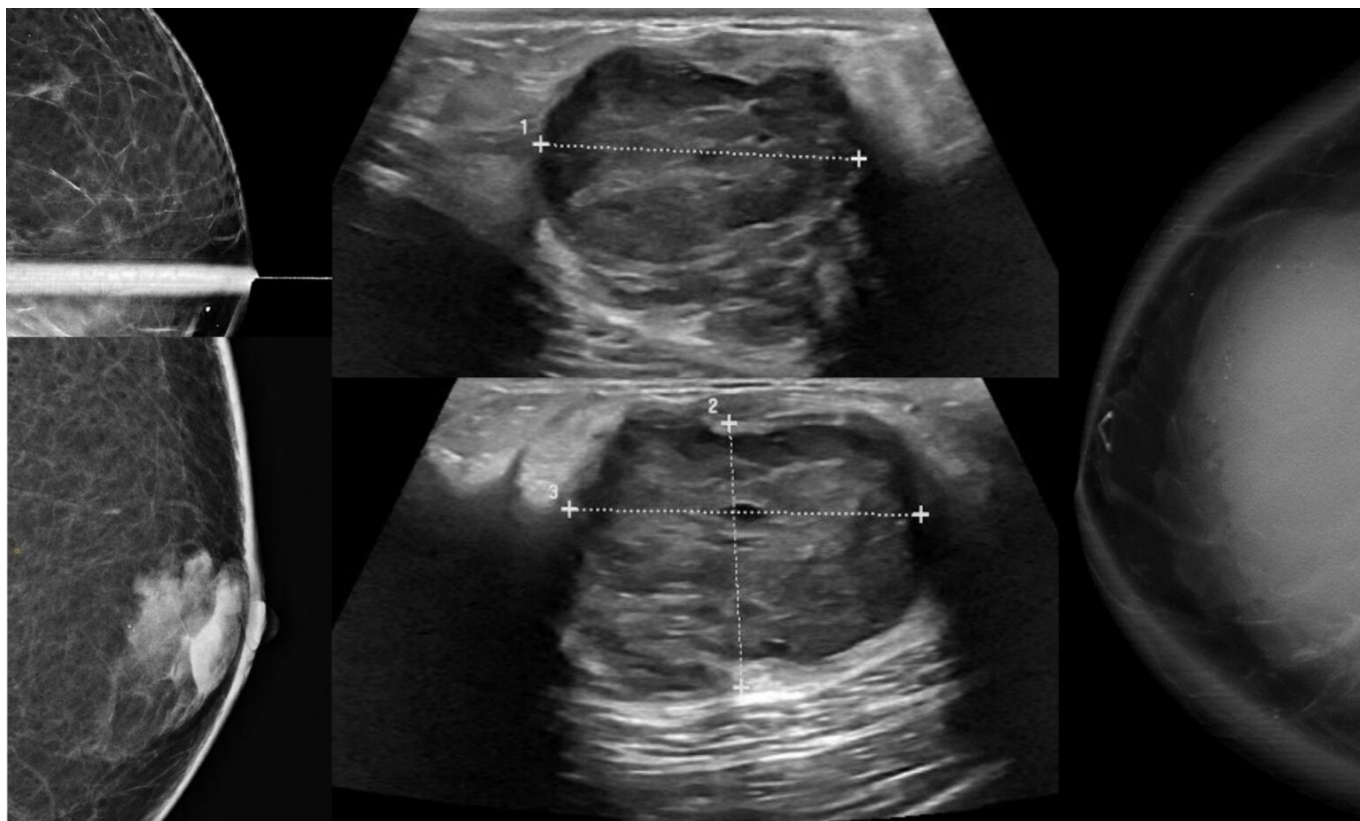


## [Breast Cancer Awareness Month: Interesting cases from RP radiologists](#)

**October is Breast Cancer Awareness Month, and all month, we're sharing interesting cases from the Radiology Partners' national subspecialty division (NSD) for breast imaging.**

Copyright 2024 Radiology Partners | All Rights Reserved. References to Radiology Partners includes its managed physician-owned and operated radiology practices which are licensed to practice medicine. Radiology Partners, Inc. is not licensed to practice medicine and does not provide patient care.

[info@radpartners.com](mailto:info@radpartners.com)

 radiology partners®




Dr. Dana Bonaminio

Our NSD is made up of practicing breast imaging radiologists from across the entire practice. As the lead for the NSD, I partner with a small team of subspecialty experts that make up an advisory board. We aim to enhance best practice recommendations, elevate image quality and patient care and update current standards throughout RP's network of practices, all to deliver excellent radiology services to patients, referring clinicians and client partners.

Part of that is sharing what we see and what we learn. Throughout the month, check back here and on [Twitter](#), [LinkedIn](#) and [Instagram](#) to see interesting cases and our findings.

# Bilateral Axillary Palpable Masses


---



This case shows a 65-year-old woman presenting with bilateral axillary palpable areas of concern for three months.

# Papilloma Involving DCIS

---

 radiology partners®

This case includes a 70-year-old woman, called back for a right breast focal asymmetry from a screening mammogram.


Copyright 2024 Radiology Partners | All Rights Reserved. References to Radiology Partners includes its managed physician-owned and operated radiology practices which are licensed to practice medicine. Radiology Partners, Inc. is not licensed to practice medicine and does not provide patient care.

[info@radpartners.com](mailto:info@radpartners.com)

 radiology partners®

# Multiple Bilateral Masses


---



This case shows a 20-year-old female showing multiple bilateral palpable areas with an enlarging mass in the right breast.

# Rare Male DCIS

---

 radiology partners®

This case shows a 77-year-old male with a palpable mass in the right breast.


Copyright 2024 Radiology Partners | All Rights Reserved. References to Radiology Partners includes its managed physician-owned and operated radiology practices which are licensed to practice medicine. Radiology Partners, Inc. is not licensed to practice medicine and does not provide patient care.

[info@radpartners.com](mailto:info@radpartners.com)

 radiology partners®

## An Unfortunate Example of how the Pandemic has Delayed Care

---



This case includes a 53-year-old female with an enlarging mass in the right breast.

See more about how we've recognized previous Breast Cancer Awareness Months. Visit [our 2021 blog](#) where breast imaging radiologists shared why they chose their subspecialty and [our 2022 blog](#) featuring a radiologist going the extra mile to provide mammography and other radiology services in hard-to-reach places.

*[Radiology Partners](#), through its owned and affiliated practices, is a leading physician-led and physician-owned radiology practice in the U.S. Learn more about our mission, values and practice principles at [RadPartners.com](#). For the latest news from RP, follow along on our [blog](#) and on [Twitter](#), [LinkedIn](#), [Instagram](#) and [YouTube](#). Interested in learning about career opportunities? [Visit our careers page](#).*